



Extraspinal findings on routine lumbar spinal MR imaging: Prevalence and etiologies in 4012 patients

Emine Dagistan  · Zeliha Cosgun

Department of Radiology, Bolu Abant Izzet Baysal University, Medical School, Bolu, Turkey

ABSTRACT

Aim: To investigate the prevalence and reporting rates of incidental findings (IF) in the routine magnetic resonance imaging (MRI) of the lumbar spine, and to emphasize their clinical importance.

Methods: A total of 4012 lumbar MRI taken between January 2014 and December 2016 were reevaluated. The low back pain and sciatalgia those suspected for lumbar spinal pathology were chosen for this study. Extra-spinal abnormalities were classified according to a modified CT Colonography Reporting and Data System (C-RADS) and analyzed.

Results The mean age of patients was 49, 83 (range 17-87) years. Of the cases, 2472 were women and 1540 were men. In 3834 cases, disk pathology was observed. In 1282 cases extraspinal pathology was detected. The largest group in the study consisted of C-RADS E2 with 1048 patients (82.5%). There were 195 patients (28.3%) in the C-RADS E3 group and 23 (1.8%) patients in the C-RADS E4 group, potentially important.

Conclusion: Our results show that random extra-spinal abnormalities in the lumbar spine MRI, are very common and systematic evaluation and proper reporting of MRI are crucial.

Keywords: Low back pain, sciatalgia, magnetic resonance imaging, extraspinal pathologies, incidental findings.

© 2020 [experimentalbiomedicalresearch.com](http://www.experimentalbiomedicalresearch.com)

✉ Dr. Emine Dagistan,
Department of Radiology, Bolu Abant Izzet Baysal
University, Medical School, Bolu, Turkey
E-mail: yemined@gmail.com
Received: 2019-12-03 / Revisions
Accepted: 2020-01-23 / Publication Date: 2020-03-06

Introduction

Since the widespread use of picture archiving and communication system (PACS) for image evaluation in most clinics, Incidental findings (IF) which are unrelated to the primary symptoms of the patient, have been observed more frequently in routine lumbar spine

magnetic resonance imaging (MRI) [1-5]. Most of IF (>95%) had no clinical significance but sometimes clinically important and life-threatening conditions like aneurysms, malignancies of other intraabdominal organs can be detected if imaging carefully evaluated for other organs inside the field of view [1-3]. The detection of these extra findings also brings variety of practical and ethical issues related to clinical management of the patient [3]. There are some studies in the literature about the frequencies of these IF, legal and cost issues of the additional examinations for the determined

pathology [1-6]. In addition, Quattrocchi et al. [3] used the modified CT colonography reporting and data system (C-RADS) for the first time in this area, which reported a wide range of random extraspinal pathologies found during lumbar magnetic resonance (MR) exams.

The aim of this study is to investigate the prevalence and reporting rates of incidental findings in the routine lumbar MRI, and to emphasize their clinical importance.

Materials and Methods

Study design

Lumbar MRI examinations, which were performed due to the preliminary diagnosis of lumbar disc herniation between January 2014 and December 2016, were retrospectively analyzed from the PACS of our radiology department to determine extraspinal pathologies. These were patients admitted to the hospital due to back and leg pain and suspected lumbar spinal pathology. The study was reviewed and approved by the local ethics committee (Decision no: 128/2017-10-04). All procedures performed in this study were in accordance with the ethical standards of the institutional and/or national research committee and with the 1964 Helsinki declaration and its later amendments or comparable ethical standards.

Patients with a known history of malignancy and multiple lumbar MRI examinations and children under 17 years of age were excluded from this study. In addition, examinations with contrast medium administration were excluded. After excluding repeated MRI examinations of the same patient, a total of 4059 patients were examined. In addition, 47 patients were excluded from the study. These are: 23 patients under the age of 17, images of 4 patients are of

poor quality and 20 patients have malignancy. As a result, the demographic findings and extraspinal pathologies of 4012 patients were investigated.

Magnetic resonance imaging

All lumbar MR imaging examinations performed in the supine position were done with a 1.5T (Symphony TIM, Siemens, Erlangen) magnet, and our study protocol was sagittal T1- and T2-weighted sequences, axial T2-weighted sequences, and a sagittal counting image covering the entire vertebral column to evaluate the transitional vertebrae. The detailed MR imaging protocol included sagittal plane turbo spin echo T2-weighted sequences (slice thickness: 4.0 mm; field of view: 32 × 32 cm; TR/TE: 594/13 ms) and axial turbo spin echo T2-weighted sequences (slice thickness: 3.0 mm; field of view: 28×23 cm; TR/TE: 5280/94 ms).

Data analysis

All MR images were evaluated in different sessions by at least two radiologists who are experts in this field. Generally, incidental extraspinal pathologies include anatomical anomalies (variants such as retroaortic renal vein and horseshoe kidneys, cysts of solid organs such as liver kidney), reproductive system pathologies (ovarian cysts, uterine fibrosis, endometrial thickening...), tumors of the abdomen and pelvic organs and other findings such as hematosalpinx, hydronephrosis, aortic aneurysms, gallstones, intestinal diverticulosis.

Extra-spinal abnormalities were classified according to a modified CT Colonography Reporting and Data System (C-RADS) [3]. During the review of the MR imaging reports clinically significant findings (E3 and E4 according to modified C-RADS classification),

benign conditions (C-RADS E2) and anatomic variations were noted. C-RADS E1 category included only anatomic variants, within the C-RADS E2 category were clinically unimportant findings for which no further work-up or assessment was indicated (e.g renal cyst, diverticulosis), the C-RADS E3 category included incompletely defined, indeterminate and most likely benign findings (e.g minimally complex renal cyst, hydronephrosis) for that further investigation(s) is indicated by clinical correlation, the C-RADS E4 category designated for potentially important findings which requires further investigations and communication with the referring physician (e.g. solid renal mass, abdominal aortic aneurysm). If there were multiple extraspinal findings in the MR imaging examination, the study was categorized according to most important clinical abnormality.

All measurable results of patients such as demographic data, MR findings and adapted CRADS classifiers were uploaded to the database and descriptive statistics were made.

Results

Extraspinal pathologies were investigated in 4012 patients, 1540 of the patients were men and 2472 were women. In our study the mean age of patients was 49, 83 (range 17-87) years. In 3834 cases, disc pathology was observed.

In 1282 cases extraspinal pathology was detected. 16 cases with anatomical variations were included in the C-RADS E1 category. Table 1 shows the distribution of pathologies in the C-RADS E2, E3 and E4 groups. The largest group in the study consisted of C-RADS E2 with 1048 patients (82.5%). There were 195 patients (28.3%) in the C-RADS E3 group and 23 (1.8%) patients in the C-RADS E4 group.

Significant vascular extraspinal abnormalities such as aortic aneurysm and retroaortic renal

vein were found (Figure 1). The presence of aortic aneurysm (C-RADS E4) has a potentially serious clinical condition. Retroaortic left renal vein can cause urological symptoms such as inguinal or flank pain and hematuria (C-RADS E3). In Table 1, very different potentially important (C-RADS E4) and likely unimportant (C-RADS E3) extraspinal findings of the genitourinary system are presented. Recurrence of renal cell carcinoma was detected in one case (C-RADS E4) (Figure 2). Potentially important various uterine findings like endometrial hyperplasia, endometrium carcinoma, cervix carcinoma and hematosalpinx were found (Figure 3). Uterine leiomyoma (fibroid) commonly seen as a mural, subserosal or submucosal mass (Figure 4).

Various gastrointestinal extraspinal findings such as diverticulosis, liver metastasis (Figure 5) and cholelithiasis were found, matching the C-RADS E4 and C-RADS E3 classification (Table 1). Iliac benign bone cysts were found as an extraspinal findings on lumbar MR images (Table 1).

Discussion

Many extraspinal pathologies may be found in the images of patients who underwent lumbar MRI research for low back and leg pain [7]. Sometimes these coincidental findings may be more important than spinal pathologies, so the management of the patient might change and cause medicolegal implications for the radiologists. [1]. Evaluation of the images in the PACS had offered additional information and higher detection of these incidental extraspinal findings, including the region out of interest and sagittal T1-weighted localizer sequence for the vertebral body counting [6]. Therefore, radiologists should try to review all information in PACS in order to detect potentially important incidental findings [6].

Table 1. Summary of IF, classified according to the modified C-RADS classification.

Organ/system	Finding	Number	Rate (%)	Men	Women
C-RADS E 2: clinically unimportant findings—no further work-up indicated					
Kidney	Cystic lesion	668	52.7	410	258
	Horseshoe kidney	6	0.47	3	3
	Staghorn stone	3	0.23	2	1
Uterus	Solid benign lesion	156	12.32	0	156
	Adenomyosis	74	5.8	0	74
Ovaries	Cystic lesion	75	5.9	0	75
	PCOS	6	0.47	0	6
	Endometrioma	4	0.31	0	4
Prostate	Hyperplasia	1	0.07	1	0
Bladder	Bladder diverticulosis	3	0.23	3	0
	Stone	2	0.15	2	0
Bowel	Diverticulosis	17	1.34	7	10
	Duplication cyst	1	0.07	0	1
Gall bladder	Cholelithiasis	12	0.94	4	8
Diaphragm	Hiatal hernia	13	1.02	6	7
Incisional hernia		2	0.15	1	1
Abdominal LAP		2	0.15	2	0
Subcutaneous lipoma		3	0.23	1	2
Total E 2		1048	82.55	442	606
C-RADS E 3: likely unimportant findings, incompletely characterized					
Vascular system	Aortic dilatation	50	3.9	31	19
	Retroaortic left renal vein	3	0.23	1	2
Kidney	Hydronephrosis	64	18.1	34	30
	Neurogenic bladder	2	0.15	1	1
	Renal atrophy	16	1.26	7	9
	Polycystic kidney disease	1	0.07	1	0
Uterus	Endometrial hyperplasia	31	2.44	0	31
Liver	T2W hyperintense lesion	23	1.81	10	13
Iliac bone cyst		4	0.31	1	3
Pelvic lenfangioma		1	0.07	0	1
Total E 3		195	28.34	86	109
C-RADS E 4: potentially important findings					
Aortic aneurysms		8	0.63	5	3
Recurrent renal cell carcinoma		1	0.07	0	1
Endometrium carcinoma		11	0.86	0	11
Cervical carcinoma		1	0.07	0	1
Hematosalpinx		1	0.07	0	1
Liver metastasis		1	0.07	0	1
Total E 4		23	1.81	5	18
Total		1266	100.0	533	733

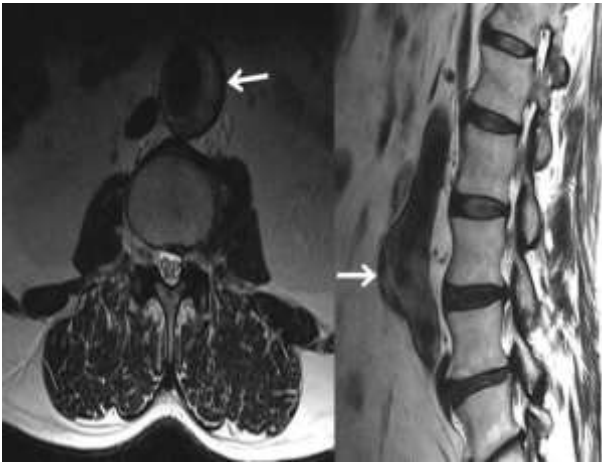


Figure 1. Fusiform aneurysm with T2-weighted axial sagittal MRI with a thrombus thickness of 17 mm, starting from the infrarenal level in a 70-year-old male patient.

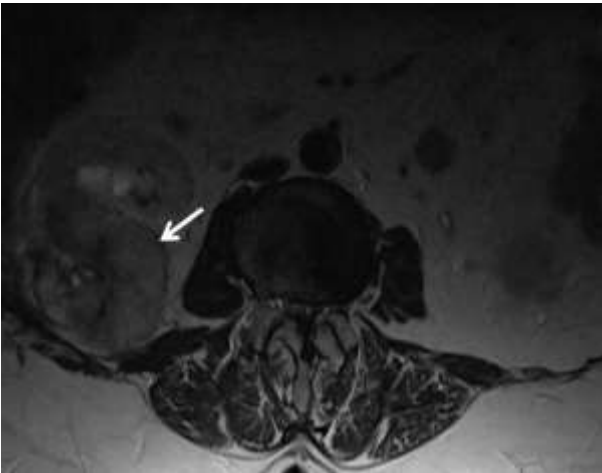


Figure 2. Recurrent mass on axial T2-weighted image in a 66-year-old woman with operated RCC.

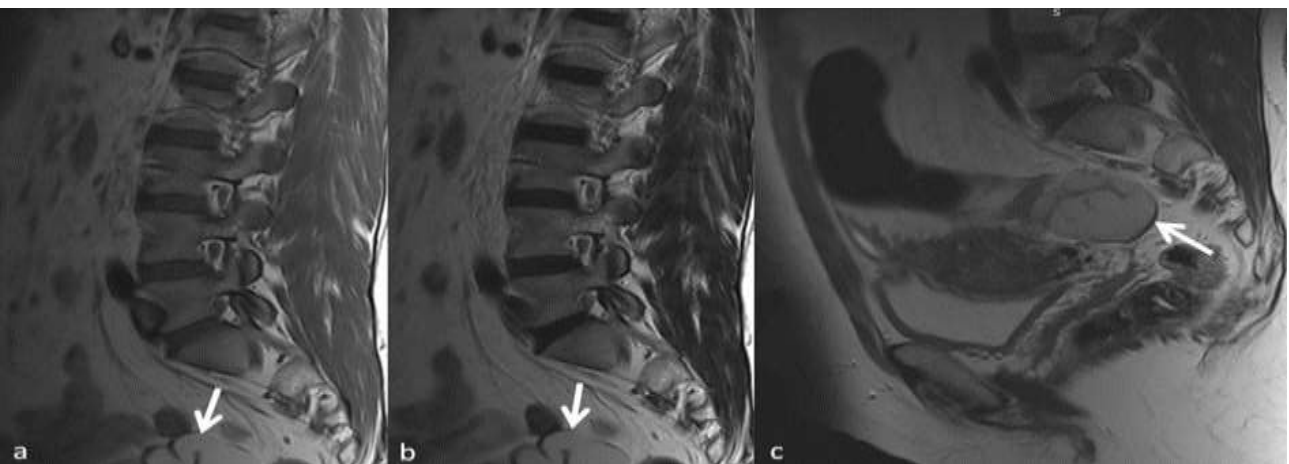

Figure 3. Hyperintense tortuous tubular structures in sagittal T1A (a) and T2A lumbar MR images of a 45 year old female patient with low back pain. Lumbar MRI will not reveal pain herniation or degeneration findings. In the pelvic MRI taken on the passage of pain, (c) both tubs are full of dilate, tortuosity and blood.

Due to the widespread use of picture archiving communication systems for the last two decades, a large increase has been recorded in the number of incidental findings identified in lumbar MRI [8,9]. As expected, with the advent of gradually advanced imaging techniques, it is understood that incidental findings are increasingly detected in other anatomical regions in addition to the lumbar spine. A similar trend has also been described in brain imaging like in the article by Vernouij et al [9]. Lee et al. [10] reported that 4.6% of IF was clinically significant in lumbar computed tomography (CT) scans, such as renal mass, aortic aneurysm, and lymphadenopathy. In the study of Zidan et al. [11], in 90 (23.7%) of 379 patients examined, the incidental findings were detected in the MRI scans of the lumbar spine. They argued that some of these findings were not clinically relevant because they were not associated with diseases or causes that initiated the diagnostic imaging test, other findings were important, and their early detection played an important role in associated treatment and prevention, potentially reduced morbidity and mortality rates. Tuncel et al [12] re-evaluated totally 1278 lumbar MRI. Among them, 34 (2.2%) clinically important incidental findings

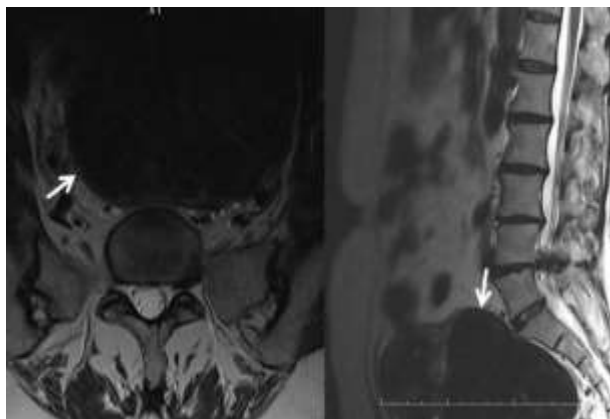


Figure 4. A hypointense mass in the uterine corpus in axial and sagittal T2A-weighted images in a 51-year-old woman.

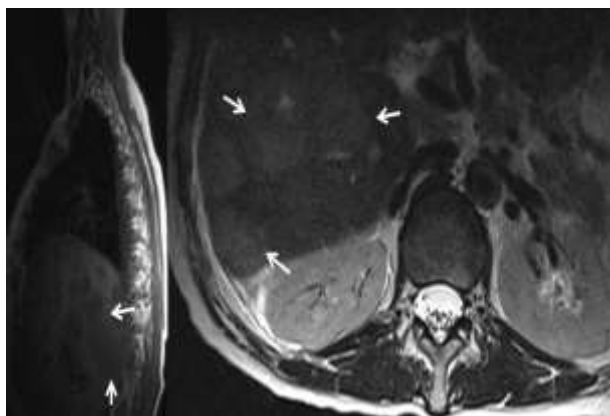


Figure 5. Liver metastatic solid lesions in sagittal localization and axial T2-weighted images in the liver of a 55-year-old woman.

were reported. They suggested that incidental findings which are clinically important occasionally omitted from routine lumbar MRI reports. Therefore, detailed examination of the lumbar MRI and extraspinal structures can be important for patient's clinical evaluation in daily practice. Fu et al. [6] screened 5104 patients who experienced low back pain or sciatica and patients with extraspinal malignancies seen in both CT and MRI were enrolled and analyzed. The prevalence of newly diagnosed extraspinal malignancies were 0.5%. The possible reason may be due to these lesions that induce low back and/or leg pain like degenerative disc disease. Quattrocchi et al [3].

3,000 lumbar spine MRI examination was analyzed retrospectively. In their studies, extraspinal findings were found in 2,060 (68.6%) of 3,000 lumbar spine MRI examinations; In 362 (17.6%) patients had indeterminate or clinically important findings (E3 and E4) requiring clinical correlation or further evaluation. After reviewing the original archived radiological reports, potentially significant C-RADS E3 and E4 extra spinal IF were reported in 47 of 265 (17.7%) and 8 of 74 patients (10.8%). We screened 4012 patients who experienced low back and leg pain who underwent routine non-enhanced MRI examinations and, extraspinal findings were detected in 840 (21%) patients. 358 (9%) of the patients had indeterminate or clinically signs (C-RADS E3/E4) which requires clinical evaluation or further investigation. Among these incidental extraspinal findings, 39 were important; 12 aortic aneurysms (1.4%), 1(0.1%) relapsed renal cell carcinoma, 18 (2%) lymphadenopathies, 6 (0.7%) cases of cervix or endometrial thickening, 1 (0.1%) hematosalpinx and 1 (0.1%) liver metastasis.

Our study has some limitations. First, our study is a retrospective research. Second, follow-up examinations of the patients with clinical significance in the classification of E3 and E4 are missed. However, the fact that our study is a large cohort study and the C-RADS classification system offers useful results in this area.

Conclusion

Extraspinal findings are frequently encountered in lumbar MRI examinations. Although most of the findings are not clinically important, some of them are important due to the fact that it might affect the life quality of the patient or might be life threatening. Therefore, proper reporting of MRI scans both identifies

clinically important IF and can also prevent medico-legal consequences for the radiologist. In addition, the radiologist should add the examinations of the organs outside from the spinal region to the systemic evaluation in order to prevent overlooking the malignancies of the surrounding tissues which might be asymptomatic.

Funding: *There is no financial support and sponsorship*

Conflict of Interest: *The authors declare that they have no conflict of interest.*

Ethical statement: *The study was reviewed and approved by the local ethics committee (Decision no: 128/2017-10-04).*

ORCID iD of the author(s)

Emine Dagistan /0000-0002-0202-8555

Zeliha Cosgun /0000-0003-1996-1568

References

- [1] Gebara NV, Meltzer DE. Extraspinal findings on lumbar spine MR imaging. *J Radiol Case Rep.* 2009; 3(8):5-13.
- [2] Kamath S, Jain N, Goyal N, et al: Incidental findings on MRI of the spine. *Clin Radiol.* 2009; 64(4):353-61.
- [3] Quattrocchi CC, Giona A, Di Martino AC, et al. Extra-spinal incidental findings at lumbar spine MRI in the general population: a large cohort study. *Insights Imaging.* 2013; 4(3):301-308.
- [4] Xiong T, Richardson M, Woodroffe R, et al: Incidental lesions found on CT colonography: their nature and frequency. *Br J Radiol.* 2005; 78(925):22-29.
- [5] Konnak JW, Grossman HB. Renal cell carcinoma as an incidental finding. *J Urol.* 1985; 134(6):1094-1096.
- [6] Fu CJ, Chen HW, Wu CT et al. Extraspinal Malignancies Found Incidentally on Lumbar Spine MRI: Prevalence and Etiologies. *J Radiol Sci.* 2013; 38(3): 85-91.
- [7] Park HJ, Jeon YH, Rho MH, et al. Incidental findings of the lumbar spine at MRI during herniated intervertebral disk disease evaluation. *AJR Am J Roentgenol.* 2011;196(5):1151–55.
- [8] Wagner SC, Morrison WB, Carrino JA, et al: Picture archiving and communication system: effect on reporting of incidental findings. *Radiology.* 2002; 225(2):500-505.
- [9] Green L. PACS: effect on incidental findings. *Radiology Manage.* 2003; 26(1):26-29.
- [10] Lee SY, Landis MS, Ross IG, Goela A, Leung AE. Extraspinal findings at lumbar spine CT examinations: prevalence and clinical importance. *Radiology.* 2012;263:502–509.
- [11] Zidan MMA, Hassan IA, Elnour AM, et al. Incidental extraspinal findings in the lumbar spine during magnetic resonance imaging of intervertebral discs. *Heliyon.* 2018;4(9):e00803.
- [12] Tuncel SA, Çağlı B, Tekataş A, et al. Extraspinal Incidental Findings on Routine MRI of Lumbar Spine: Prevalence and Reporting Rates in 1278 Patients. *Korean J Radiol.* 2015;16(4):866–73.