



## Surgical treatment with rhomboid excision and Limberg flap technique under spinal anesthesia of 23 young with pilonidal sinus disease

Hulya Ozturk<sup>1</sup>, Hamit Yoldas<sup>2</sup>, Ibrahim Karagoz<sup>2</sup>

<sup>1</sup>Department of Pediatric Surgery, Abant Izzet Baysal University Hospital, Bolu, Turkey

<sup>2</sup>Department of Anesthesiology, Abant Izzet Baysal University Hospital, Bolu, Turkey

### ABSTRACT

**Aim:** To present the experience of treatment with Limberg flap procedure under spinal anesthesia in 23 young patients with pilonidal sinus disease.

**Methods:** This was a retrospective study of 23 young patients who underwent surgery for pilonidal sinus disease under spinal anesthesia between January 2011 and November 2017 in the Division of Pediatric Surgery. All patients were evaluated for age, sex, clinical diagnosis, and body mass index, and infection, duration of symptoms, treatment, healing time, recurrences, complications and results.

**Results:** Of the 23 patients, 4 (17%) were male, and 19 (83%) were female. The mean age of the patients was  $15.21 \pm 2.8$  years and the mean symptom duration was  $4 \pm 2.6$  months. In 13 patients (56.5%), there was one or more sagittal lines in the midline and the mean sinus number of the patients was  $2.12 \pm 0.60$ . Pain was the most important complaint affecting the quality of life of the patient. The mean body mass index was  $26.33 \pm 2.54$  kg / m<sup>2</sup>, and 47.8% (n = 11) were high BMI and 53.2% were normal BMI. One patient had temporary headache and one patient had urinary retention. Wound infection occurred in 2 patients (8.6%). Recurrence was not observed in patients.

**Conclusion:** In this study, pilonidal sinus disease was treated with Limberg flap procedure under spinal anesthesia. The combination of these two applications in patients with pilonidal sinus may provide significant advantages, such as rapid recovery and short hospital stay, early return to daily activities, low complications, and recurrence rates.

**Keywords:** Pilonidal sinus, young, Limberg flap, spinal anesthesia, complications.

Copyright © 2018 [experimentalbiomedicalresearch.com](http://www.experimentalbiomedicalresearch.com)

**Corresponding Author:** Hulya Ozturk, M.D.  
Abant Izzet Baysal University, Medical School,  
Department of Pediatric Surgery, Bolu, Turkey  
E-mail: [hulya\\_ztrk@yahoo.com](mailto:hulya_ztrk@yahoo.com)  
Received 2017-11-25 Accepted 2018-01-27

### Introduction

The incidence of pilonidal sinus has been reported to be approximately 26 / 100,000 [1]. The term "pilonidal" originating from the Latin word "pilus" refers to hair and nidus. Pilonidal sinus disease, first described by Hodges in 1880, is an abnormal type of chronic skin infection associated with trapped hair [2,3].

Pilonidal sinus disease is almost completely visible on the sacrococcygeal area [4]. Although acquired or congenital hypotheses have been proposed for pilonidal sinus disease, the etiology is not fully understood. However, excessive hair, obesity, prolonged sitting, local irritation, family history and inadequate personal hygiene are among the etiologic causes [5].

Although there is no conclusive evidence for the best method of surgical treatment of pilonidal sinus disease, it has been suggested some variable approaches such as simple incision and drainage, unroofing sinus tracts with marsupialization, and wide excision with healing by secondary intention or primary closure with or without the creation of a flap [6]. Schmittner et al. [7] showed that patients who were treated under spinal anesthesia had a shorter time spent in the recovery room, earlier oral feeding, no sore throat complaints, less postoperative nausea and vomiting, and less analgesic requirements.

In this study, we reviewed the experience of patients who were diagnosed with pilonidal sinus disease and underwent Limberg flap procedure under spinal anesthesia.

## **Methods**

This retrospective study is the evaluation of 23 young patients who underwent spinal anesthesia for pilonidal sinus disease between January 2011 and November 2017 in our clinic. Inclusion criteria were all children with infected, symptomatic pilonidal disease. All patients were evaluated for age, sex, clinical diagnosis, and body mass index (BMI), and infection, duration of symptoms, treatment, healing time, recurrences, complications and results. The patients' BMI was determined as normal weight (5 to 85%), overweight (85 to 95%) or obese (95%) [8]. All patients were

given antibiotic prophylaxis (cefazolin 50 mg/kg) preoperatively.

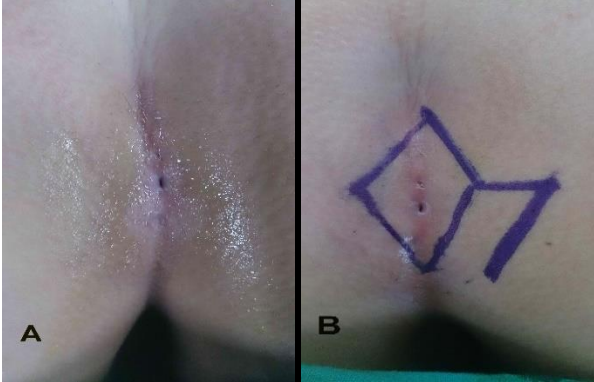
## ***Spinal anesthesia***

Spinal anesthesia was managed under aseptic conditions using midline approach in sitting position. 7.5 mg hyperbaric bupivacaine (Bustesin 0.5%, Vem Ilac. San Tic Ltd., Turkey) was injected into the subarachnoid space of the L3-L4 or L4-L5 with a 27-G Whitacre pencil-point needle. The sensory block of all patients was tested by an anesthesiologist. During this period, the patients were kept in the 30 ° up position for 10 minutes. Optionally, midazolam was titrated slowly (range of 0.5-1 mg) until a light level of sedation was reached—an observer's assessment of alertness/sedation score of 4–5. At this time, oxygen saturation and semi-quantitative carbon dioxide were measured, and adequate respiration was provided. After surgery, patients were discharged from the operation room when they awake, alert, and oriented to time and place, were experiencing only minimal nausea without vomiting, and when room air SpO<sub>2</sub> was at least 95%. Patients were discharged from the post-anesthesia care unit (PACU) using the Aldrete discharge criteria and from the SU using the post-anesthesia discharge criteria [9,10].

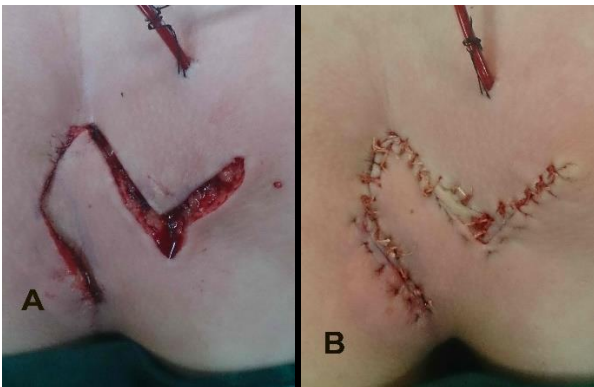
## ***Surgical procedure and postoperative follow-up***

All surgical procedures were performed by one pediatric surgeon under spinal anesthesia. First, the patients were placed in the prone position, jack-knife position, and the sacrococcygeal region was taken to lateral traction with the help of adhesive tape. Then, the surgical area was prepared with 10% povidone-iodine. In addition, the margins of the sinus tract were tried to be determined by

injecting methylene blue and palpation. Firstly, the area within the pilonidal sinus borders was marked as described in the original Limberg flap technique [Fig. 1A, B].



**Fig. 1. A)** Preoperative view of pilonidal sinus. **B)** Romboïd-Flap (Limberg).



**Fig. 2. A, B.** Early view of the repair with Limberg flap.

Secondly, a rhomboid-shaped excision was made on the sinus tract at the marked border, and then the sinus was completely removed to the presacral fascia using an electrocautery. The Limberg flap was mobilized, and transposed medially without any tension. Then, the all layers were closed with vicryl sutures [Fig. 2A, B]. Additionally, one hemovac drain was placed on the presacral fascia. In the first postoperative hour, patients were allowed to drink fluid through the mouth. The patients were mobilized 12 hours postoperatively and hemovac drainage was

withdrawn on the third postoperative day or when the drainage decreased to 10 cc / day. It was suggested that they should not sit on their incisions, by using an inflatable ring pillow or sitting side by side for 15 days when they were discharged to the hospital, and they were told that they could sit normally on the incision after 1 month. Heavy exercises were not allowed for 3 months, and it was suggested that the patients shave in the gluteal region 6 months after the operation. Patients were followed for 1 year, and the complications were noted. The opening of the wound was considered secondary to infection or suture removal. The patients were also asked for any numbness in the gluteal region.

## Results

In this study, of the 23 patients, 4 (17%) were male, and 19 (83%) were female. The mean age of the patients was  $15.21 \pm 2.8$  (12-18) years and the mean symptom duration was  $4 \pm 2.6$  (range, 1.6-12) months. In 13 patients (56.5%), there was one or more sagittal lines in the midline and the mean sinus number of the patients was  $2.12 \pm 0.60$  (1-4).

Major complaints of the patients were pain, mass or swelling and purulent secretion. Particularly, pain was found to be a complaint affecting the quality of life of the patient. The mean body mass index was  $26.33 \pm 2.54$  kg / m<sup>2</sup>, and 47.8% (n = 11) were high BMI and 53.2% were normal BMI.

The SpO<sub>2</sub> values of the patients remained stable throughout the study period. No other complications such as hypotension, bradycardia, nausea or vomiting were observed in the cases. No back pain or transient neurological symptoms developed in any patient postoperatively. One patient had temporary headache and one patient had urinary retention.

The mean duration of hospital stay was  $4.51 \pm 2.85$  (range: 2-19) days. There was no wound opening or flap necrosis in any of the patients. Wound infection occurred in 2 patients (8.6%). Oral antibiotics were used for infection treatment and were treated with local wound care within 2 weeks. Mean time returned to daily, and military activity was  $17.20 \pm 3.56$  (range, 12–27) days. Recurrence was not observed in patients.

### **Discussion**

In etiology of pilonidal sinus disease, some risk factors such as obesity, excessive hair growth, bad hygiene, prolonged sitting, family history and trauma have been suggested [5,11,12]. Among these reasons, there is debate about whether obesity is an important factor in the formation of pilonidal sinus disease [13-15]. In this retrospective study, 47.8% of patients had a BMI of 25 or greater. However, we are on the verge of supporting existing data with controlled studies. Additionally, Bascom et al. suggested that the hair in this region is a causal agent in the pilonidal sinus. They concluded that the midline pits in the natal cleft are enlarged and contain distorted hair follicles, and that these follicles are pushed along the base [16,17]. Pilonidal sinus disease is a pathology most seen in young adults and generally affects boys three times more often than girls [18]. The girl:boy ratio of 5:1 in this series is not the same as that reported elsewhere [19-21], but the mean age of  $15.21 \pm 2.8$  (12-18) years was similar.

Although the best treatment approach for pilonidal sinus disease has not yet been established, several treatment procedures such as primary excision with or without closure, marsupialization or different flap techniques have been proposed [22]. However, the

common goal is to be easy to apply, the patient returns to daily activities in a short time, and the recurrence rate is low. The en bloc excision of the pilonidal sinus is another preferred common view. Nevertheless, it should not be forgotten that the actual problem after excision of the sinus tract is reconstruction of the removed region. In addition, today, the treatment of pilonidal sinus disease has been tried in different non-surgical methods such as phenol administration, cryosurgery and shaving [23-25]. Rhomboid excision and Limberg flap method have been reported to have a faster recovery time, lower recurrence and postoperative complication rate than excision and primer closure [26,27]. It has been reported that recurrence rates of pilonidal sinus disease with Karydakias flap repair are 1-4%, and 1-6% with Limberg flap treatment [28-30]. In this study, we chose the Limberg flap surgery technique for treatment of pilonidal sinus disease cases due to the above reasons. We did not have a recurrence in our study but this may also be related to the low patient count. Montes et al [31] believed that closed suction drain is not necessary after Limberg flap operation. In their study, 353 patients underwent surgery with a Limberg flap and no close suction drain was used; infection rate 6.5%, seroma 2.2% [31]. Additionally, Erdem et al. [32] did not find any statistical significant differences between the groups using and not using draining in terms of hospital stay, infection, and hematoma rate. In this study, closed suction drains were used in all operated patients. Laser-assisted epilation has been reported to give good results in the sacrococcygeal region after pilonidal sinus surgery [22,33,34]. Braungartet al also considered that the preliminary results in this regard are promising. We have laser hair removal in our dark-haired patients.

Due to the localization of the pilonidal sinus, various clinical studies have been conducted on a suitable anesthesia technique for more advantageous management of postoperative processes. Anesthetic methods include general anesthesia, spinal anesthesia (SPA), local anesthesia and tumescent local anesthesia [35-37]. Patients generally tend to prefer general anesthesia, but spinal anesthesia offers many advantages because of its ease of performance, continuity of hemodynamic stability, and low incidence of complications [38]. However, the prone position during pilonidal sinus surgery can cause central and peripheral nerve injuries, arterial and venous occlusion, ophthalmic and pressure injuries as well as changes in cardiovascular and respiratory physiology in patients [39]. In data analyses of a retrospective study, Luedi et al [40] suggested that SPA or general anesthesia does not influence long term recurrence of the disease and postoperative pain. In another study, Schmittner et al [41] shown that spinal anesthesia with 7.5 mg hyperbaric bupivacaine is superior to total intravenous anesthesia in patients undergoing pilonidal sinus operations in prone position in terms of analgesia consumption in recovery room, recovery times and postoperative complications.

This study has several limitations. First of all, it is a retrospective serie with a limited number of patients. The results of a single surgical technique made by a single surgeon were presented. For this reason, it is difficult to make any statistical conclusions. Therefore, we believe that a prospective study with more patients and different techniques is required.

### **Conclusions**

We think that Limberg flap surgery technique with spinal anesthesia is one of the most appropriate methods for sacrococcygeal

pilonidal sinus disease according to the low recurrence rates and short hospital stay.

### **Compliance with ethical statements**

*Conflicts of Interest:* None.

### **References**

- [1] McCallum I, King PM, Bruce J. Healing by primary versus secondary intention after surgical treatment for pilonidal sinus. *Cochrane Database Syst Rev*. 2007;(4):CD006213.
- [2] Hodges RM. Pilonidal sinus. *Boston Med Surg J*. 1880;103:485–86.
- [3] Corman ML. Cutaneous condition. In: Cormon ML (ed) *Colon and rectal surgery*, 3rd edn. Lippincott, Philadelphia, 1999. pp 374–435.
- [4] Aysan E, Ilhan M, Bektas H, Kaya EA, Sam B, Buyukpinarbasili N, Muslumanoğlu M. Prevalence of sacrococcygeal pilonidal sinus as a silent disease. *Surg Today*. 2013;43(11):1286-9.
- [5] Harlak A, Menten O, Kilic S, Coskun K, Duman K, Yilmaz F. Sacrococcygeal pilonidal disease: analysis of previously proposed risk factors. *Clinics (Sao Paulo)*. 2010;65(2):125–31.
- [6] Fike FB, Mortellaro VE, Juang D, Ostlie DJ, St Peter SD. Experience with pilonidal disease in children. *J Surg Res*. 2011;170(1):165-68.
- [7] Schmittner MD, Dieterich S, Gebhardt V, Weiss C, Burmeister MA, Bussen DG, et al. Randomised clinical trial of pilonidal sinus operations performed in the prone position under spinal anaesthesia with hyperbaric bupivacaine 0.5% versus total intravenous anaesthesia. *Int J Colorectal Dis*. 2013;28(6):873-80.
- [8] Yildiz T, Ilce Z, Küçük A. Modified Limberg flap technique in the treatment of

- pilonidal sinus disease in teenagers. *J Pediatr Surg*. 2014;49(11):1610-13.
- [9] Chernik DA, Gilings D, Laine H, Hendler J, Silver JM, Davidson AB, et al. Validity and reliability of the observer's assessment of alertness/sedation scale: study with intravenous midazolam. *J Clin Psychopharmacol*. 1990;10(4):244-51.
- [10] Sungurtekin H, Sungurtekin U, Erdem E. Local anesthesia and midazolam versus spinal anesthesia in ambulatory pilonidal surgery. *J Clin Anesth*. 2003;15(3):201-5.
- [11] Bolandparvaz S, Moghadam Dizaj P, Salahi R, Paydar S, Bananzadeh M, Abbasi HR, et al. Evaluation of the risk factors of pilonidal sinus: a single center experience. *Turk J Gastroenterol*. 2012;23(5):535-7.
- [12] Sakr M, El-Hammadi H, Moussa M, Arafa S, Rasheed M. The effect of obesity on the results of Karydakis technique for the management of chronic pilonidal sinus. *Int J Colorectal Dis*. 2003;18(1):36-39.
- [13] Yildiz T, Elmas B, Yucak A, Turgut HT, Ilce Z. Risk Factors for Pilonidal Sinus Disease in Teenagers. *Indian J Pediatr*. 2017;84(2):134-138.
- [14] Arda IS, Güney LH, Sevmiş S, Hiçsönmez A. High body mass index as a possible risk factor for pilonidal sinus disease in adolescents. *World J Surg*. 2005;29(4):469-71.
- [15] Afşarlar CE, Yılmaz E, Karaman A, Karaman I, Özgüner İF, Erdoğan D, et al. Treatment of adolescent pilonidal disease with a new modification to the Limberg flap: symmetrically rotated rhomboid excision and lateralization of the Limberg flap technique. *J Pediatr Surg*. 2013;48(8):1744-9.
- [16] Bascom J. Pilonidal disease: origin from follicles of hairs and results of follicle removal as treatment. *Surgery*. 1980;87(5):567-72.
- [17] Bascom J ( ) Pilonidal disease: long-term results of follicle removal. *Dis Colon Rectum*. 1983;26(12):800-807.
- [18] da Silva JH. Pilonidal cyst: cause and treatment. *Dis Colon Rectum*. 2000;43(8):1146-56.
- [19] Golladay ES, Wagner CW. Pediatric pilonidal disease: a method of management. *South Med J*. 1990;83(8):922-24.
- [20] Yücesan S, Dindar H, Olcay I, Okur H, Kiliçaslan S, Ergören Y, et al. Prevalence of congenital abnormalities in Turkish school children. *Eur J Epidemiol*. 1993;9(4):373-80.
- [21] Morden P, Drongowski RA, Geiger JD, Hirschl RB, Teitelbaum DH. Comparison of Karydakis versus midline excision for treatment of pilonidal sinus disease. *Pediatr Surg Int*. 2005;21(10):793-96.
- [22] Braungart S, Powis M, Sutcliffe JR, Sugarman ID. Improving outcomes in pilonidal sinus disease. *J Pediatr Surg*. 2016;51(2):282-84.
- [23] Armstrong JH, Barcia PJ. Pilonidal sinus disease. The conservative approach. *Arch Surg*. 1994;129(9):914-19.
- [24] Schneider IHF, Thaler K, Kockerling TF. Treatment of pilonidal sinuses by phenol injections. *Int J Colorectal Dis*. 1994;9(4):200-202.
- [25] Gage AA, Dutta P. Cryosurgery for pilonidal disease. *Am J Surg*. 1977;133(2):249-54.
- [26] Ertan T, Koc M, Gocmen E, Aslar AK, Keskek M, Kilic M. Does technique alter quality of life after pilonidal sinus surgery? *Am J Surg*. 2005;190(3):388-92.
- [27] Akca T, Colak T, Ustunsoy B, Kanik A, Aydin S. Randomized clinical trial comparing primary closure with the

- Limberg flap in the treatment of primary sacrococcygeal pilonidal disease. *Br J Surg.* 2005;92(9):1081-84.
- [28] Kithen PR. Pilonidal sinus: Experience with the Karydakis flap. *Br J Surg.* 1996;83(10):1452-55.
- [29] Urhan MK, Kücükel F, Topgul K, Ozer I, Sari S. Rhomboid excision and Limberg flap for managing pilonidal sinus: results of 102 cases. *Dis Colon Rectum.* 2002;45(5):656-9.
- [30] Topgül K, Ozdemir E, Kiliç K, Gökbayir H, Ferahköşe Z. Long-term results of limberg flap procedure for treatment of pilonidal sinus: a report of 200 cases. *Dis Colon Rectum.* 2003;46(11):1545-8.
- [31] Menten O, Bagci M, Bilgin T, Ozgul O, Ozdemir M. Limberg flap procedure for pilonidal sinus disease: results of 353 patients. *Langenbecks Arch Surg.* 2008;393(2):185-9.
- [32] Erdem E, Sungurtekin U, Neşşar M. Are postoperative drains necessary with the Limberg flap for treatment of pilonidal sinus? *Dis Colon Rectum.* 1998;41(11):1427-31.
- [33] Koch D, Pratsou P, Szczecinska W, Lanigan S, Abdullah A. The diverse application of laser hair removal therapy: a tertiary laser unit's experience with less common indications and a literature overview. *Lasers Med Sci.* 2015;30(1):453-67.
- [34] Ghnnam WM, Hafez DM. Laser hair removal as adjunct to surgery for pilonidal sinus: our initial experience. *J Cutan Aesthet Surg.* 2011;4(3):192-95.
- [35] Naja MZ, Ziade MF, El Rajab M. Sacrococcygeal local anaesthesia versus general anaesthesia for pilonidal sinus surgery: a prospective randomised trial. *Anaesthesia.* 2003;58(10):1007-12.
- [36] Bussen D, Sailer M, Fuchs KH, Thiede A. Tumescence local anesthesia in proctologic surgery. *Chirurg.* 2003;75(9):839-43.
- [37] Sungurtekin H, Sungurtekin U, Erdem E. Local anesthesia and midazolam versus spinal anesthesia in ambulatory pilonidal surgery. *J Clin Anesth.* 2003;15(3):201-205.
- [38] Edgcombe H, Carter K, Yarrow S. Anaesthesia in the prone position. *Br J Anaesth.* 2008;100(2):165-83.
- [39] Schmittner MD, Janke A, Weiss C, Beck GC, Bussen DG. Practicability and patients' subjective experiences of low-dose spinal anaesthesia using hyperbaric bupivacaine for transanal surgery. *Int J Colorectal Dis.* 2009;24(7):827-36.
- [40] Luedi MM, Kauf P, Evers T, Sievert H, Doll D. Impact of spinal versus general anesthesia on postoperative pain and long term recurrence after surgery for pilonidal disease. *J Clin Anesth.* 2016;33:236-42.
- [41] Schmittner MD, Dieterich S, Gebhardt V, Weiss C, Burmeister MA, Bussen DG, Viergutz T. Randomised clinical trial of pilonidal sinus operations performed in the prone position under spinal anaesthesia with hyperbaric bupivacaine 0.5 % versus total intravenous anaesthesia. *Int J Colorectal Dis.* 2013;28(6):873-80.