


**Effects of evening primrose oil and 5-fluorouracil on the healing of colonic anastomoses in rats**

Gokhan Selcuk Ozbalci¹ · Hamza Cinar² · Ismail Alper Tarim¹ · Tugrul Kesicioglu³  · Kagan Karabulut¹ · Aysu Basak Ozbalci⁴ · Bahattin Avci⁵ · Ayfer Kamali Polat¹ · Levent Yildiz⁶ · Kenan Erzurumlu¹

¹Department of General Surgery, Ondokuz Mayıs University, Medical Faculty, Samsun, Turkey

²Department of General Surgery, Ordu University, Medical Faculty, Ordu, Turkey

³Department of General Surgery, Giresun University, Medical Faculty, Giresun, Turkey

⁴Department of Radiology, Samsun Training and Research Hospital, Samsun, Turkey

⁵Department of Medical Biochemistry, Ondokuz Mayıs University, Medical Faculty, Samsun, Turkey

⁶Department of Pathology, Ondokuz Mayıs University, Medical Faculty, Samsun, Turkey

ABSTRACT

Aim: This study was designed to evaluate the efficacy of evening primrose oil (EPO) on colonic anastomosis.

Methods: Sixty rats with colonic anastomosis were randomly divided into six groups. EPO and 5-Fluorouracil (5-FU) were administered at doses of 5 g/kg/day and 20 mg/kg/day, respectively. Group 1 served as sham control. The rats in Group 2 (EPO) received EPO (14 days preoperatively), in Group 3 (Extended EPO) received EPO (14 days preoperatively and 7 days postoperatively), in Group 4 (5-FU) received intraperitoneally 5-FU (5 days preoperatively), in Group 5 (5-FU+EPO) received EPO (14 days preoperatively), and 5-FU (5 days preoperatively), in Group 6 (5-FU+ extended EPO) received EPO (14 days preoperatively and 7 days postoperatively) and 5-FU (5 days preoperatively). Histopathological examination, bursting pressure, and hydroxyproline content were used for evaluation.

Results: Significant differences were found between the Groups 1, 2, and 3 and Groups 4, 5, and 6 in bursting pressures. Polymorphonuclear leukocyte (PMNL) and lymphocyte infiltration was significantly less in group 3, compared to the control and group 2. The least PMNL infiltration was in group 6 compared to groups 4 and 5. The hydroxyproline level was different in group 3 compared to the control and group 2. Furthermore, groups 5 and 6 were different compared to group 4.

Conclusion: EPO had favorable effects on colonic anastomosis even in groups where 5-FU was used.

Keywords: Anastomotic healing, evening primrose oil, 5-fluorouracil, bursting pressure.

© 2020 [experimentalbiomedicalresearch.com](http://www.experimentalbiomedicalresearch.com)

✉ Dr. Tugrul Kesicioglu, Department of General Surgery, Giresun University, Medical Faculty, Giresun, Turkey.

E-mail: drkescolu@gmail.com

Received: 2019-10-17 / Revisions: 2019-11-15

Accepted: 2019-12-03 / Publication Date: 2020-01-01

Introduction

Anastomotic leakage is a major problem that significantly increases mortality and morbidity in colorectal surgery. The incidence is 0.5-30% in the literature [1,2]. A mortality rate of 25-37% has been reported due to anastomotic leakage in a large series [3]. Anastomotic failure increases the duration of hospitalization 2-fold and perioperative mortality 3-fold [4]. Therefore, research is focused on a variety of systemic or local interventions with the hope of favorable effects on anastomosis healing [1,2,4-6].

5-fluorouracil (5-FU) application has been regarded as the standard chemotherapy agent for colorectal cancer for a long time [7]. The postoperative intraperitoneal application of 5-FU is known to clear disseminated cancer cells and eradicate micrometastases [4,8]. However, 5-FU has also been shown to negatively affect healing in colonic anastomosis in several studies [9-11]. It was shown that 5-FU increases inflammatory reaction, reduces the fibroblast and collagen formation and neovascularization at the anastomotic site [11].

Evening primrose oil (EPO) is rich in omega-six and essential fatty acids such as linoleic acid (LA) and gamma linoleic acid (GLA). These fatty acids are prostaglandin precursors and used in the production of prostaglandin-E1 (PGE1) exogenously [12]. PG-E1 has been demonstrated to favorably affect anastomotic healing in various studies [13-15]. PG-E1 exerts its effect by promoting the collagen synthesis and decreasing the inflammatory cell infiltration that negatively affect the process of anastomotic healing [14,15].

EPO, as a rich PG-E1 source, has vasodilator, anti-oxidative and anti-inflammatory effects when used in high doses [12]. It has been the subject of many studies due to its effects and found a place in the treatment of many diseases

[16-18]. However, to the best of our knowledge, its effects on anastomotic healing has yet to be elucidated. The aim of this study is to evaluate the effects of EPO on colonic anastomosis in a rat experiment.

Materials and Methods

This study was approved by the Ethics Board of 19 Mayıs University, School of Medicine (Dated 29.01.2013 and issue number 2013/07). In addition to standard groups, rat groups who were subjected to the effects of 5-FU were created. Therefore, the efficacy of EPO was evaluated in the presence of an agent that is known to have unfavorable effects on anastomotic healing.

Sixty male Wistar albino rats, weighing 250-300 g, were used in the study. The subjects were fed with tap water, standard animal feed, and EPO and were kept in a laboratory environment. A cocktail with ketamine (Ketalar®, Parke-Davis, Eczacıbaşı), 80 mg/kg and xylazine (Rompun®, Bayer), 8 mg/kg was used intraperitoneally as anesthetic agent. Following appropriate field cleansing and placing sterile sheets, a midline incision, 3-3.5 cm in length was performed. A colon resection, 1 cm in thickness, was carried out in the middle part of the transverse colon and an end-to-end anastomosis was created using a 5/0 polypropylene suture. The abdominal incision was closed using a 3/0 silk suture.

The rats were randomly divided into six groups (Figure 1). Group 1 (control) received standard feed for 14 days preoperatively and 7 days postoperatively. The rats in Group 2 (EPO) received EPO, 5 g/kg/day through gavage for 14 days preoperatively in addition to standard feed. Rats were fed with standard feed for 7 days postoperatively. The rats in Group 3 (Extended EPO) received EPO, 5 g/kg/day through gavage for 14 days preoperatively and

7 days postoperatively in addition to standard feed. The rats in Group 4 (5-FU) received intraperitoneally 20 mg/kg 5-FU (Biosyn®, Orna) diluted in 3 ml saline solution for 5 days preoperatively and resection and anastomosis was performed after an interval of 1 day. Subjects were fed with standard feed for 7 days postoperatively. The rats in Group 5 (5-FU+EPO) received EPO, 5 g/kg/day for 14 days and also intraperitoneally 20 mg/kg 5-FU diluted in 3 ml saline solution for 5 days preoperatively. Subsequently one day interval was given and resection and anastomosis were performed. Subjects were fed with standard feed for 7 days postoperatively. The rats in Group 6 (5-FU+ extended EPO) received EPO, 5 g/kg/day for 14 days and also intraperitoneally 20 mg/kg 5-FU diluted in 3 ml saline solution for 5 days preoperatively. Subsequently, a one-day interval was given and resection and anastomosis were performed. Subjects were fed with EPO, 5 g/kg/day through gavage in addition to standard feed for 7 days postoperatively. Rats were sacrificed after seven days postoperatively and after 12 hours of fasting, relaparotomies were performed.

Bursting pressure

Following relaparotomy, a segment of the colon, measuring 5 cm in length, 2.5 from each direction from the anastomosis, was resected carefully. This segment of the transverse colon was cleaned of feces and the distal end was tied with a 3/0 silk suture. A catheter connected to a sphygmomanometer was inserted to the proximal end and colon was carefully tied around the tube. A solution of 0.9% NaCl was infused at a constant speed of 1ml/min through the catheter. The level of pressure seen when the leakage appeared at the anastomosis was recorded. All the bursting pressures were

evaluated immediately after the rats were sacrificed.

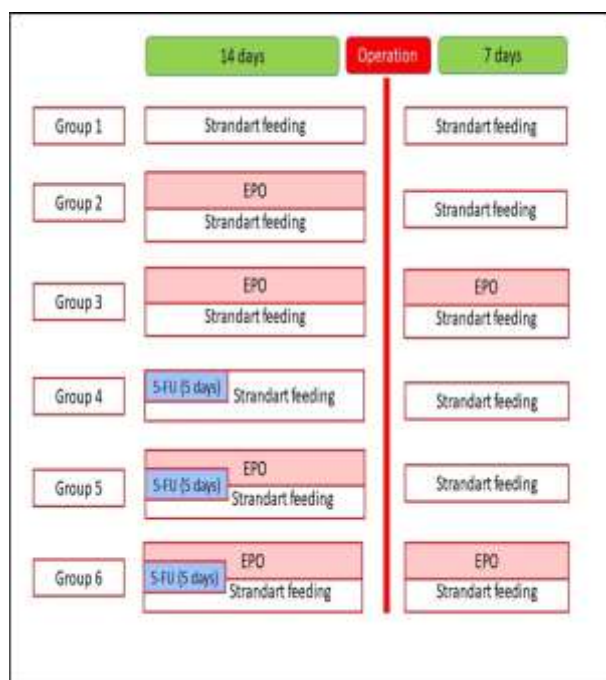


Figure 1. Diagram of experimental design.

Histopathological examination

Following the recording of the bursting pressure, the anastomosis line was resected, including approximately 0.5 cm proximal and distal colonic segments. The resected segment of colon was divided into two parts in equal lengths and one of the pieces was placed in a 10% buffered neutral formalin solution for histopathological examination. Evaluation was performed after staining with Hematoxylin Eosin (HE) using a semi-quantitative scale including many parameters related to wound healing, as defined by Biert et al. [19] (Table 1). According to this scale, the amount of necrosis was expressed as none (0 points), only small patches (1 point), some patches (2 points), or massive (3 points). In the anastomotic area, accumulation of polymorphonuclear cells (PMNs), macrophages, and lymphocytes was also assessed in terms of none or normal (0 points), slightly increased (1 point), marked infiltration (2 points), and massive infiltration

(3 points). Edema, expressed as the ratio of maximum thickness of the wall at the anastomosis and the thickness of the normal colon wall at the end of the section, was graded as none (0 points), some (1–1.5× normal thickness; 1 point), marked (1.5–2× normal thickness; 2 points) and severe (> 2x normal thickness; 3 points). Healing of the mucosa was expressed as normal, i.e. mucosa with restored glandular epithelium (0 points), intact mucosa with cubic epithelium but without glands (1 point), mucosa only partially covered by cubic epithelium (2 points), and mucosa completely devoid of epithelial coverage (3 points). Submucosal-muscular repair was assessed in terms of good (0 points), average (1 point), poor (2 points), or no (3 points) fibroblast stretching and bridging the anastomotic wound. This way, in each anastomosis, two observations from the mesenteric and two from the anti-mesenteric side were performed.

Hydroxyproline

The second piece taken from the anastomotic line was manually homogenized applying liquid nitrogen in a porcelain mortar and placed in an appropriately buffered phosphate solution (Phosphate Buffer Solution, 10 mM, pH 7.2). Following the sonication of the tissue samples for 1 minute in +4°C at 220V (Fisher, Sonic

Dismembrator; Mosel 300), they were stored in a freezer at -80 °C. Homogenates were centrifuged at +4°C at 14000 rpm for 5 minutes and the obtained supernatants were used for analysis. Hydroxyproline levels were determined using a BioVision commercial kit (BioVision, CA, USA, Cat.No.#K555-100) based on reading at 560 nm of chromogen, which is formed as a result of a spectrophotometric reaction. The protein content of each sample in tissue homogenates was determined using the Lowry method [20] and levels of hydroxyproline were expressed in ng per mg protein (ng/mg.prot).

Statistical analysis

When Groups I, II, and III and Groups IV, V, and VI were compared within groups, and the characteristics of hydroxyproline and bursting pressure were evaluated one-way analysis variance (ANOVA) was used. Levene's homogeneity test was used to detect the homogeneity of the variances.

The Kruskal-Wallis test was used in the analysis of other features. The analysis of hydroxyproline levels and bursting pressure characteristics were performed using independent sample t-test in inter-group comparisons. The Mann-Whitney U-test was used in the analysis of other

Table 1. Scores are used to analyze semi-quantitatively the healing of anastomosis line in colon.

Score	Necrosis	PMN	Lymphocytes	Macrophages	Edema	Mucosal Epithelium	Submucosal -Muscular Layer
0	None	Normal pumber	Normal number	Normal Number	None	Normal glandular	Good bridging
1	Small patches	Slight increase	Slight increase	Slight increase	Some	Normal cubic	Average bridging
2	Some patches	Marked infiltration	Marked infiltration	Marked infiltration	Marked	Incomplete cubic	Poor bridging
3	Massive	Massive infiltration	Massive infiltration	Massive infiltration	Severe	Absent	No bridging

characteristics. P values <0.05 were accepted as statistically significant.

Results

Bursting pressure

The highest bursting pressure values were measured in the extended EPO group (198.0 ± 7.48). The lowest bursting pressures were in the 5-FU group (119.89 ± 2.88). Statistically

significant differences were found between the intergroup analysis of Groups I, II, and III and between Groups IV, V, and VI (p<0.001) (Table 2).

Differences were reported between the control group and 5-FU group and between the EPO group and 5-FU+EPO group, as well (p<0.001). In addition, statistically significant differences were found between the extended EPO and 5-FU+ extended EPO groups (p=0.002) (Table 3).

Table 2. Hydroxyproline content levels and bursting pressure values according to group a#b#c.

Groups	Hydroxyproline (ng/mL)	Bursting Pressure (mmHg)
Control	1113.41 ± 62.32b	144.6 ± 3.81c
EPO	1380.98 ± 59.39b	177.4 ± 7.66b
Extended EPO	1915.08 ± 318.89a	198.0 ± 7.48a
<i>P value</i>	0.014	0.001
5- FU	789.23 ± 129.73b	119.89 ± 2.88c
5-FU+EPO	1183.48 ± 52.71a	136.40 ± 4.51b
5-FU+Extended EPO	1249.83 ± 58.54a	158.33 ± 7.26a
<i>P value</i>	0.002	0.001

Values: SEM, EPO: evening primrose oil, 5-FU: 5- fluorouracil.

Table 3. Hydroxyproline content levels and bursting pressure values according to groups a#b.

Groups	Hydroxyproline (ng/mL)	Bursting Pressure (mmHg)
Control	1113.41 ± 62.32a	144.6 ± 3.81a
5- FU	789.23 ± 129.73b	119.89 ± 2.88b
<i>P value</i>	0.045	<0.001
EPO	1380.98 ± 59.39a	177.4 ± 7.66a
5-FU+EPO	1183.48 ± 52.71b	136.40 ± 4.51b
<i>P value</i>	0.023	<0.001
Extended EPO	1915.08 ± 318.89	198.0 ± 7.48a
5-FU+Extended EPO	1249.83 ± 58.54	158.33 ± 7.26b
<i>P value</i>	0.057	0.002

Values: SEM, EPO: evening primrose oil, 5-FU: 5- fluorouracil.

Histopathological examination

When the control, EPO and extended EPO groups were compared, it was observed that PMNL and lymphocyte infiltration was significantly lower in the extended EPO group compared to the other two groups ($p=0.003$, and $p=0.020$). No differences were found in other histopathological examination criteria (Table 4). When the groups with 5-FU were compared, a significant difference between all groups was found in only the PMNL infiltration. The lowest PMNL infiltration was in the 5-FU+extended EPO group and was different from the other two groups ($p=0.029$). Other criteria of histopathological examination were found to be similar in the groups (Table 4). Figures 2-4 show histopathological changes and inflammatory findings in different treatment groups.

When the groups with and without chemotherapeutic agents were comparatively

analyzed, significant differences were found in macrophage infiltration, edema formation, and mucosal epithelial structure between the control and 5-FU groups ($p=0.005$, $p=0.025$, and $p=0.008$, respectively). Macrophage infiltration and mucosal epithelial damage was significantly higher in the 5-FU group. In addition, more edema development was seen in this group. Mucosal epithelial structure was different in the EPO and 5-FU+EPO groups. The mucosal epithelial damage was more severe in the 5-FU+EPO group ($p=0.030$). When the extended EPO and 5-FU+extended EPO groups were compared, edema development and mucosal epithelial damage was significantly greater in the 5-FU+extended EPO group ($p=0.005$ and $p=0.048$, respectively). Other histopathological evaluation criteria were similar in all groups (Table 5).

Table 4. The results of histopathological examination according to groups $a \neq b$.

Groups	Necrosis	PMNL	Lymphocytes	Macrophages	Edema	Submucosal-ML	Mucosal Epithelium
Control	0 (0-0)	2(0-3)a	1 (0-3)a	0 (0-1)	1(0-2)	0 (0-0)	0 (0-0)
EPO	0 (0-3)	1(0-2)a	1 (0-2)a	1 (0-1)	1(0-2)	0 (0-3)	0 (0-0)
Extended EPO	0 (0-0)	0(0-1)b	0 (0-1)b	0 (0-1)	0(0-1)	0 (0-0)	0 (0-2)
<i>P value</i>	0.387	0.003	0.020	0.483	0.215	0.387	0.329
5- FU	0 (0-3)	1(1-3)a	1(1-2)	1 (1-2)	1(1-3)	0 (0-0)	2 (0-3)
5-FU+EPO	0 (0-3)	1(0-2)ab	0.5(0-2)	0.5 (0-2)	1(0-3)	0 (0-0)	0 (0-3)
5FU+Extended EPO	0 (0-3)	0(0-2)b	0 (0-2)	0 (0-2)	1(1-3)	0 (0-2)	2 (0-3)
<i>P value</i>	0.814	0.029	0.072	0.072	0.068	0.348	0.851

Values: Median (Min – Max), EPO: evening primrose oil, 5-FU: 5- fluorouracil, ML: Muscular Layer, PMNL: polymorphonuclear leukocyte.

Table 5. The results of histopathological examination according to groups a≠b.

Groups	Necrosis	PMN	Lymphocytes	Macrophages	Edema	Submucosal-ML	Mucosal epithelium
Control	0(0-0)	2(0-3)	1(0-3)	0(0-1)b	1(0-2)b	0(0-0)	0(0-0)b
5-FU	0(0-3)	1(1-3)	1(1-2)	1(1-2)a	1(1-3)a	0(0-0)	2(0-3)a
<i>P</i> value	0.125	0.428	0.882	0.005	0.025	1.000	0.008
EPO	0(0-3)	1(0-2)	1(0-2)	1(0-1)	1(0-2)	0(0-3)	0(0-0)b
5-FU+EPO	0(0-3)	1(0-2)	0.5(0-2)	0.5(0-2)	1(0-3)	0(0-0)	0(0-3)a
<i>p</i> value	0.542	0.314	0.188	0.993	0.720	0.739	0.030
Extended EPO	0(0-0)	0(0-1)	0(0-1)	0(0-1)	0(0-1)b	0(0-0)	0(0-2)b
5FU+Extended EPO	0(0-3)	0(0-2)	0(0-2)	0(0-2)	1(1-3)a	0(0-2)	2(0-3)a
<i>P</i> value	0.313	0.873	0.873	0.873	0.005	0.73	0.048

Values: Median (Min – Max), EPO: evening primrose oil, 5-FU: 5- fluorouracil, ML: Muscular Layer, PMNL: polymorphonuclear leukocyte.

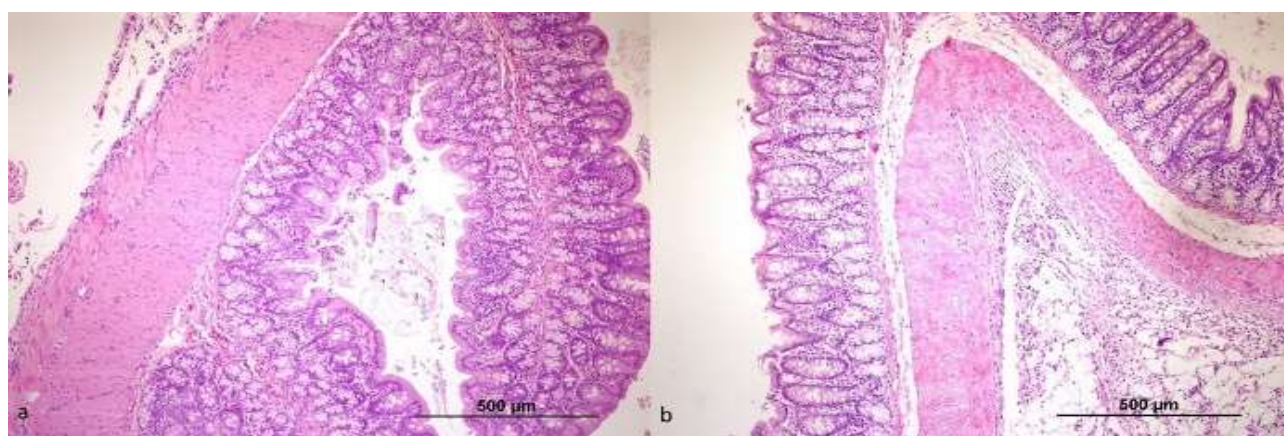


Figure 2. a) Mucosa is intact in the extended EPO group; acute and chronic inflammation are minimal (x100HE). b) Mucosa is in atrophic appearance in the control group, chronic active inflammation which is evident especially in serosa (x100 HE).

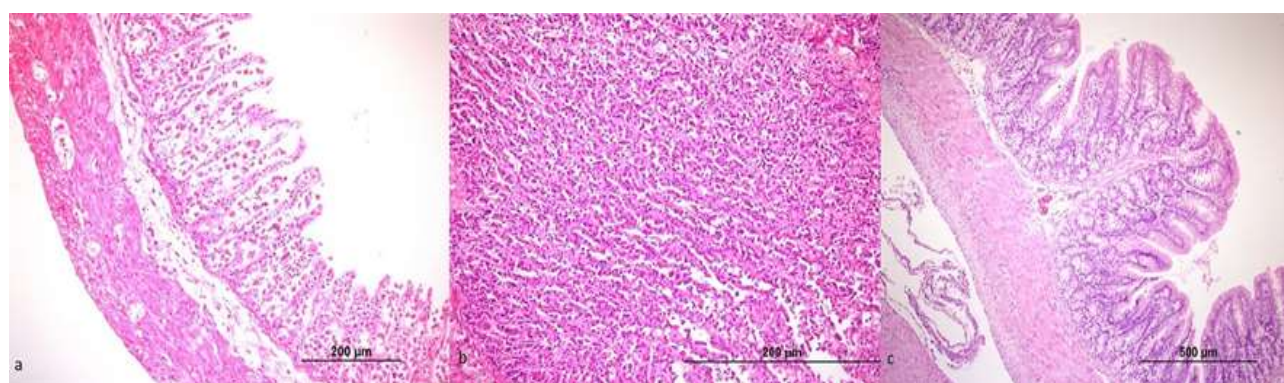


Figure 3. a) Extended necrosis and active inflammation present in mucosa and submucosa in the 5-FU group (x200HE). b) Extensive macrophage infiltration in lamina propria in the 5-FU group (x400 HE). c) Intact mucosa, minimal inflammation, no macrophage infiltration in the control group (x100HE).

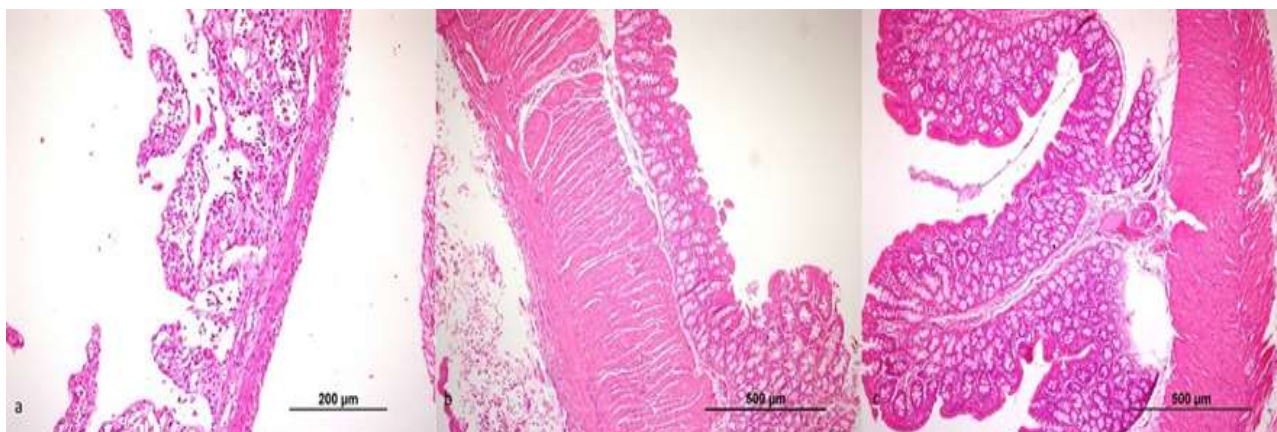


Figure 4. a) Extended ischemic damage is present in mucosa and submucosa in the 5-FU group. Intensive chronic and active inflammatory cells are seen (x200 HE). b) Mucosa with atrophic morphology and mild inflammatory cells are seen in 5-FU + EPO group (x100 HE). c) Intact mucosal and submucosal layers and minimal inflammatory cells are seen in the 5-FU + extended EPO group (x100 HE).

Hydroxyproline

Hydroxyproline levels in the extended EPO group was different when compared to the control and EPO groups ($p=0.014$). The 5-FU+EPO and 5-FU+extended EPO groups were also significantly different from the 5-FU groups, as well ($p=0.002$) (Table 2).

When the groups with and without chemotherapeutic agents were comparatively evaluated, differences were found between the control and 5-FU groups and between EPO and 5-FU+EPO ($p=0.045$ and $p=0.023$, respectively) (Table 3).

Discussion

The salient finding of the present study was that EPO demonstrated beneficial therapeutic effects of on colonic anastomosis in rats. These favorable effects were still prominent in the presence of 5-FU that has deleterious effects on the anastomosis.

Anastomotic leakage after colorectal surgery is reported to be seen in up to 30% of the cases. [1,2,4,9]. In spite of the advances in the operative techniques and patient preparation procedures it is still a significant cause of postoperative morbidity and mortality [3].

Anastomotic healing is a complex process including a series of biological events. Coordination of cellular activity and humoral factors is necessary during this process [21]. Anastomotic healing is affected by the degree of the inflammatory response and the rate of mucosal re-epithelization, thus the power, quantity, and maturation rate of the collagen. Durability of the anastomosis line is basically dependent on the collagen fibrils and their degree of maturation in the submucosa [22]. We found that administration of EPO had a clear beneficial effect on both bursting pressures and hydroxyproline content. Hydroxyproline content was significantly higher in the extended EPO group compared to the other groups on the seventh day when we expected the collagen synthesis to be at its highest level. We also observed that 5-FU significantly decreased the hydroxyproline content. The adverse effect of 5-FU on fibroblast proliferation and collagen synthesis is well-known [7]. On the contrary, the observed higher hydroxyproline content in the 5-FU+EPO and 5-FU+extended EPO groups compared to the 5-FU group demonstrated that EPO reverses the deleterious effects of 5-FU.

Experimental studies have demonstrated that the hydroxyproline concentrations decrease in the anastomotic lines after colonic resections [15]. Hawley et al. [23] emphasized that the collagenase enzyme was responsible for the observed decrease in the level of hydroxyproline. Hawley et al. demonstrated that the production of this enzyme was increased both in the area of anastomosis and also in other parts of gastrointestinal system. This is a primary factor causing weakness of the anastomosis by increasing collagen breakdown. Therefore, the production and breakdown of collagen during the healing phase of the anastomosis should be well balanced.

The authors have stressed that it is necessary to prevent low suture tension, good local blood flow, weak local inflammation, and to reduce feces by a lavage of colon preoperatively for a good anastomotic healing after colonic surgery. These factors may have an effect on collagen synthesis by inhibiting collagenase. As a result, collagen content in the intestinal wall plays a major role in anastomotic healing and the prevention of complications such as leakage [15].

Since fibroblast proliferation and collagen synthesis occur in the submucosal layer, anastomotic strength primarily depends on the collagen fibrils in the submucosa, as stated above [21]. Maximal collagen synthesis occurs in the 5-7th days during the proliferation of local fibroblasts which produce collagen [22]. Therefore, this study was terminated on the 7th day, taking into account the experimental models in the literature [22,24].

EPO is a product that has been used for years as a dietary supplement and an alternative treatment in various diseases [12,16]. It is most commonly used in the treatment of diseases with chronic inflammation. Atopic dermatitis, rheumatoid arthritis, mastalgia, menopausal

and premenstrual symptoms, cervical ripening, and birth induction are some of the conditions for which it is frequently used [16-18]. It is rich from omega-6 essential fatty acids such as LA and GLA, which are used in the production of PGE1 in the body [12]. Orally administered EPO has been proven to demonstrate vasodilator, anti-oxidative, and anti-inflammatory efficacy in various experimental studies [12,25]. Abo-Gresha et al. [12] demonstrated the healing effect of EPO in rats with experimentally-induced myocardial infarction. In that study, in addition to the antithrombotic activity of PGE1, which is synthesized from the fatty acids in EPO, it is reported to cause smooth muscle relaxation and vasodilation. Furthermore, PGE1 was reported to decrease oxidative stress and inflammation in the ischemic heart. El-Sayed et al. [25] on the other hand, in their experimental study, in which they evaluated the progression of rheumatoid arthritis, reported that EPO has a marked anti-inflammatory effect. In addition, they recorded that GLA, which increases the production of PGE1 in the body had a role in the anti-inflammatory and anti-oxidative effects. In experimental studies, the predominant vasodilator, anti-inflammatory and wound healing effects of PGE1 have been emphasized. Goertz et al. [26] evaluated the effects of various agents such as acetylsalicylic acid, isosorbide dinitrate, sodium chloride, and PGE1, which were considered to have treatment effect in rats with experimentally produced burns. The most successful results were obtained in the PGE1 group. PGE1 was proven to increase angiogenesis and blood flow and at the same time to demonstrate anti-inflammatory effects by decreasing rolling leukocytes in the circulation. Its effects on augmentation of wound healing by increasing perfusion through inducing vasodilation,

inhibiting thrombocyte aggregation, and thus delaying thrombus formation have also been reported. Kobayashi et al. [27] also demonstrated that PGE1, in addition to its vasodilator and anti-aggregating effects on thrombocytes, proliferates the production of epidermal keratinocytes and dermal fibroblasts. In addition, they reported that PGE1 was an anti-oxidative agent and all of its characteristic features have a positive effect on wound healing.

The limitation of the current work deserves to be stated. We applied 5-FU and EPO in a single dose in all groups. We determined the dose of EPO as 5 g/kg/day based on the results of previous studies in the literature [25,28,29], in which the dose of EPO varied between 1.25-10 g/kg/day and for an average of 14-28 days. We also determined the dose and duration of 5-FU in the appropriate groups according to the previous studies [7,10]. To limit the number of scarified animals and not to increase complexity of the experimental model, we opted for using a single EPO and 5-FU dose in the study.

For the first time in the literature, we evaluated the effects of EPO administered through the gavage method on colonic anastomosis in an experimental study. We administered the agent for 14 days preoperatively and 7 days postoperatively in the respective groups.

Conclusions

In conclusion, we demonstrated beneficial therapeutic effects of EPO on colonic anastomosis in rats. This was likely due to the essential fatty acid content of EPO because these fatty acids are used in the production of PGE1 in the body. The anti-inflammatory, vasodilator and anti-oxidative effects of EPO might favorably influence the anastomosis. The maintenance of these favorable effects in spite

of the presence of an agent that has deleterious effects on the anastomosis such as 5-FU suggests that EPO use might be employed to decrease the rate of anastomotic leakage in patients who receive neoadjuvant chemotherapy and are scheduled to undergo surgical treatment.

Funding: *There is no financial support and sponsorship*

Conflict of Interest: *The authors declare that they have no conflict of interest.*

ORCID ID of Authors

Gokhan Selcuk Ozbalci /0000-0003-0768-8306

Hamza Cinar / 0000-0003-1748-1392

Ismail Alper Tarim / 0000-0002-6203-2644

Tugrul Kesicioglu / 0000-0002-9263-5032

Kagan Karabulut / 0000-0003-4723-5360

Aysu Basak Ozbalci / 0000-0001-9974-5974

Bahattin Avci / 0000-0001-6471-6495

Ayfer Kamali Polat / 0000-0001-6414-9435

Levent Yildiz /0000-0001-5516-7172

Kenan Erzurumlu /0000-0001-9245-8083

References

- [1] Caglayan K, Erdogan N, Avci B, et al. Effect of Beta-glucan on intestinal anastomoses in a rat model. *Adv Clin Exp Med*. 2013; 22(2):157-63.
- [2] Yaman I, Kara C, Dericci H, et al. The effect of a special amino acid mixture on healing of left colonic anastomosis: an experimental study. *Turkiye Klinikleri J Med Sci*. 2013;33(3):678-84.
- [3] Kanellos I, Blouhos K, Demetriades H, et al. The failed intraperitoneal colon anastomosis after colon resection. *Tech Coloproctol*. 2004; 8 :53-5.
- [4] Zacharakis E, Demetriades H, Pramateftakis MG, et al. Effect of IGF-I on healing of colonic anastomoses in rats under

- 5-FU treatment. *J Surg Res.* 2008;144(1):138-44.
- [5] Uludag M, Citgez B, Ozkaya O, et al. Effects of amniotic membrane on the healing of normal and high-risk colonic anastomoses in rats. *Int J Colorectal Dis.* 2009; 24(7):809-17.
- [6] Symeonidis N, Papakonstantinou E, Psarras K, et al. The effect of celecoxib administration on the healing and neovascularization of colonic anastomosis in rats. *J Invest Surg.* 2014; 27(3):139-46.
- [7] Ozel L, Ozel MS, Toros AB, et al. Effect of early preoperative 5-fluorouracil on the integrity of colonic anastomoses in rats. *World J Gastroenterol.* 2009; 15(33):4156-62.
- [8] Vaillant JC, Nordlinger B, Deuffic S, et al. Adjuvant intraperitoneal 5-fluorouracil in high-risk colon cancer: A multicenter phase III trial. *Ann Surg.* 2000; 231(4):449-56.
- [9] Kanellos D, Pramateftakis MG, Demetriades H, et al. Healing of colonic anastomoses after immediate postoperative intraperitoneal administration of oxaliplatin. *Int J Colorectal Dis.* 2008;23(12):1185-91.
- [10] Kanellos D, Pramateftakis MG, Mantzoros I, et al. The effects of the intraperitoneal administration of oxaliplatin and 5-FU on the healing of colonic anastomoses: an experimental study. *Tech Coloproctol.* 2011; 15 :111-15.
- [11] Pramateftakis MG, Kanellos D, Mantzoros I, et al. Intraperitoneally administered irinotecan with 5-fluorouracil impair wound healing of colonic anastomoses in a rat model: an experimental study. *Tech Coloproctol.* 2011; 15 :121-25.
- [12] Abo-Gresha NM, Abel-Aziz EZ, Greish SM. Evening primrose oil ameliorates platelet aggregation and improves cardiac recovery in myocardial-infarct hypercholesterolemic rats. *Int J Physiol Pathophysiol Pharmacol.* 2014; 6(1):23-36.
- [13] de Oliveira PG, Soares EG, Aprilli F. Influence of misoprostol, a synthetic prostaglandin E1 analog, on the healing of colonic anastomoses in rats. *Dis Colon Rectum.* 1994; 37(7):660-63.
- [14] Cali RL, Smyrk TC, Blatchford GJ, et al. Effect of prostaglandin E1 and steroid on healing colonic anastomoses. *Dis Colon Rectum.* 1993; 36(12):1148-51.
- [15] Terzioglu T, Sonmez YE, Eldegez U. The effect of prostaglandin E1 on colonic anastomotic healing. A comparison study. *Dis Colon Rectum.* 1990; 33(1):44-8.
- [16] Bayles B, Usatine R. Evening primrose oil. *Am Fam Physician.* 2009; 80(12):1405-8.
- [17] Farzaneh F, Fatehi S, Sohrabi MR, et al. The effect of oral evening primrose oil on menopausal hot flashes: a randomized clinical trial. *Arch Gynecol Obstet.* 2013;288(5):1075-79.
- [18] Senapati S, Banerjee S, Gangopadhyay DN. Evening primrose oil is effective in atopic dermatitis: a randomized placebo-controlled trial. *Indian J Dermatol Venereol Leprol.* 2008; 74(5):447-52.
- [19] Biert J, Seifert WF, Verhofstad AA, et al. A semiquantitative histological analysis of repair of anastomoses in the rat colon after combined preoperative irradiation and local hyperthermia. *Radiat Res.* 1998; 149(4):372-77.
- [20] Lowry OH, Rosebrough NJ, Farr AL, et al. Protein measurement with the Folin phenol reagent. *J Biol Chem.* 1951; 193(1):265-75.
- [21] Inan A, Koca C, Sen M. Effects of diclofenac sodium on bursting pressures of anastomoses and hydroxyproline contents of perianastomotic tissues in a laboratory study. *Int J Surg.* 2006;4(4):222-27.

- [22] Aslan A, Temiz M, Hakverdi S, et al. Effect of mesalamine on healing in experimental colon anastomosis: a randomised experimental study. *Int J Surg.* 2008;6(1):40-4.
- [23] Hawley PR, Faulk WP, Hunt TK, et al. Collagenase activity in the gastro-intestinal tract. *Br J Surg.* 1970; 57(12):896-900.
- [24] Kosmidis C, Efthimiadis C, Anthimidis G, et al. Myofibroblasts and colonic anastomosis healing in Wistar rats. *BMC Surg.* 2011; 11:6.
- [25] El-Sayed RM, Moustafa YM, El-Azab MF. Evening primrose oil and celecoxib inhibited pathological angiogenesis, inflammation, and oxidative stress in adjuvant-induced arthritis: novel role of angiopoietin-1. *Inflammopharmacology.* 2014 Mar 25. [Epub ahead of print]
- [26] Goertz O, Ring A, Buschhaus B, et al. Influence of anti-inflammatory and vasoactive drugs on microcirculation and angiogenesis after burn in mice. *Burns.* 2011; 37(4):656-64.
- [27] Kobayashi H, Katakura O, Morimoto N, et al. Effects of cholesterol-bearing pullulan (CHP)-nano gels in combination with prostaglandin E1 on wound healing. *J Biomed Mater Res B Appl Biomater.* 2009;91(1):55-60.
- [28] Omran OM. Histopathological study of evening primrose oil effects on experimental diabetic neuropathy. *Ultrastruct Pathol.* 2012; 36(4):222-27.
- [29] Ford I, Cotter MA, Cameron NE, et al. The effects of treatment with alpha-lipoic acid or evening primrose oil on vascular hemostatic and lipid risk factors, blood flow, and peripheral nerve conduction in the streptozotocin-diabetic rat. *Metabolism.* 2001; 50(8):868-75.