



## The protective effects of ursodeoxycholic acid and the selective cyclooxygenase-2 inhibitor celecoxib on liver damage in an experimental cholestasis model

Adem Kucuk<sup>1</sup>, Hulya Ozturk<sup>2</sup>

<sup>1</sup>Department of Pediatric Surgery, Duzce Ataturk State Hospital, Duzce, Turkey

<sup>2</sup>Department of Pediatric Surgery, Bolu Abant Izzet Baysal University, Faculty of Medicine, Bolu, Turkey

### ABSTRACT

**Aim:** Cholestasis leads to liver cell death, fibrosis, cirrhosis, and eventually liver failure. Ursodeoxycholic acid (UDCA) is the only Food and Drug Administration-approved treatment for cholestatic disorders. Hepatic cyclooxygenase-2 (COX-2) expression increases in various chronic liver diseases caused either by viruses or toxins. The present study was conducted to investigate the effects of UDCA and the selective COX-2 inhibitor celecoxib on inflammation and fibrogenesis in a rat model of cholestasis induced by bile duct ligation (BDL).

**Methods:** Fifty Sprague–Dawley rats that underwent common BDL for 21 days were assigned to one of five treatment groups (sham-operation, BDL, daily UDCA treatment following BDL, daily celecoxib treatment following BDL, and daily celecoxib and UDCA combination treatment following BDL). Serum and liver samples were collected after 21 days. Fibrosis, ductular proliferation, and portal inflammation were scored in liver samples. Liver function tests were evaluated.

**Results:** In comparison with the control group, the BDL group showed hepatic damage as evidenced by elevation in serum biochemical and histological changes such as ductular reaction, fibrosis, and inflammation. These pathophysiological changes were attenuated by chronic UDCA and selective COX-2 inhibitor celecoxib supplementation.

**Conclusion:** Our findings indicate that the addition of Celecoxib to UDCA reduces liver inflammation and fibrosis and might be an effective supplemental therapy with UDCA for cholestatic diseases. The beneficial effects of chronic UDCA and Celecoxib supplementation may be associated with their potential cytoprotective, anti-oxidative and anti-inflammatory effects.

**Keywords:** Cholestasis, hepatic fibrosis, ursodeoxycholic acid, celecoxib, cyclooxygenase-2.

Copyright © 2019 [experimentalbiomedicalresearch.com](http://www.experimentalbiomedicalresearch.com)

Corresponding Author: Dr. Adem Kucuk  
Department of Pediatric Surgery, Duzce Ataturk State  
Hospital, Duzce, Turkey

E mail: [ademkucuk81@hotmail.com](mailto:ademkucuk81@hotmail.com)

ORCID ID: <http://orcid.org/0000-0002-2357-3712>

Received 2019-02-09, Accepted 2019-03-07

Publication Date 2019-03-14

### Introduction

Extrahepatic and intrahepatic biliary disorders can occur in newborns and adults for different reasons. Congestion and interruption can be anywhere from the porta to the duodenum. Biliary atresia is the most common cause in

neonatal period [1]. The incidence is about 1/8000 - 1/15000 worldwide [2, 3].

In clinical and experimental studies, chronic obstructive jaundice has been shown to lead to the complete closure of the extrahepatic biliary tree by causing progressive inflammation and sclerotic reactions and fibrosis in the liver [4]. In untreated babies, it results in death at an average of 8 months. The main factors causing the development of fibrosis in the liver have been shown to include portal and systemic endotoxemia, balance disorder in oxidative-antioxidant systems, and increase in the release of TNF- $\alpha$ , prostaglandins and cytokines in lipid peroxidation [5, 6]. It has been shown that liver damage can be reduced by using different drugs such as glucocorticoids, ursodeoxycholic acid (UDCA), glutamine, phenobarbital, cyclooxygenase-2 (COX-2) inhibitors, and curcumin to prevent these reported effects [5].

The aim of this study was first to induce chronic obstructive jaundice in prepubertal rats and to investigate the damage of this obstruction on the liver. Additionally, the study was designed to determine the role of COX-2 inhibitors and UDCA, which have been shown to have positive effects in the light of previous studies, in the prevention of these adverse effects in the liver when used alone and in combination.

## Methods

The study was approved by the Duzce University Animal Research Local Ethics Committee (2010/04) and was carried out in Duzce University Experimental Animals Application and Research Center. Extrahepatic biliary tract (EHBT) obstruction was performed using 50 prepubertal Sprague-Dawley male rats weighing between 120 and 220 grams. The rats were fed with standard

feed and city water before and after the procedure.

## Experimental Protocol

Ketamine hydrochloride (Ketalar®, Eczacibasi, Istanbul/Turkey) (25mg/kg, i.m.) was used as preanesthetic, and ketamine+xylazine hydrochloride were used for sedation (Rompun® 23.3 mg/ml, Bayer, Germany), (10 mg/kg and 3mg/kg, respectively, i.p.); buprenorphine (Tengesic® 0.3 mg, Schering, Germany, 0.1-0.05 mg/kg, s.c.) was used for the analgesia.

The abdominal skin of the rats was shaved, and laparotomy was performed with a midline incision under sterile conditions. Experimental cholestasis model was performed as previously described by Criado et al., and experimental groups were created [7]:

Group 1 (Sham-Control group, n = 10): By performing laparotomy, EHBT was freed only from the surrounding tissues and the abdomen was closed.

Group 2 (Group without medication, n = 10): EHBT was released from the surrounding tissues by laparotomy and was cut by 4/0 silk, and the abdomen was closed.

Group 3 (2.5 g/kg UDCA-receiving group, n = 10): EHBT was released from the surrounding tissues by laparotomy, was cut with 4/0 silk, and the abdomen was closed. UDCA (2.5 g/kg) was given using gavage tube for 21 days.

Group 4 (30 mg/kg COX-2 inhibitor group, n = 10): Laparotomy was performed to free EHBT from the surrounding tissues, EHBT was cut with 4/0 silk, and the abdominal wall was closed. The COX-2 inhibitor celecoxib (30 mg/kg) was administered by gavage tube for 21 days.

Group 5 (2.5 g/kg UDCA acid and 30 mg/kg COX-2 inhibitor group, n = 10): EHBT was released from the surrounding tissues by

laparotomy, was cut with 4/0 silk, and the abdominal wall was closed. UDCA (2.5 g/kg) and COX-2 inhibitor (30 mg/kg) were administered by gavage tube for 21 days.

During the 3-week follow-up period, four rats died in each of Groups 1 (control) and Group 2 (EHBT obstruction), while one rat died in each of Groups 3 (UDCA) and Group 4 (COX-2 inhibitor), while no rats died in Group 5 rats (UDCA and COX-2 inhibitor combination). All studies were completed with ten rats per group, with additional rats added to replace those that died during the follow-up period. Additional rats underwent the same experimental procedures.

In all groups, weight measurements were made before and three weeks after the procedure. Blood samples were obtained from the abdominal aorta for alkaline phosphatase (ALP), gamma glutamyl transferase (GGT), total bilirubin (TB), aspartate aminotransferase (AST), alanine aminotransferase (ALT) and total protein (TP) measurements at three weeks using a similar anesthesia protocol; then, rats were sacrificed by cannulation, and liver samples were taken for histopathological evaluation. Approximately 3-4 ml of blood from the abdominal aorta were taken into heparinized tubes. Blood was centrifuged to obtain plasma, and ALP, GGT, total bilirubin, AST, ALT and total protein values in plasma were measured by using Roche HITACHI Cobas 6000, a standard autoanalyzer for biochemical studies by the enzymatic colorimetric method.

Histopathological study was performed on 50 liver tissue samples taken from all rats in all five groups by hepatectomy. Liver tissues were fixed in 10% formalin. Sections from these blocks were stained with Hemotoxylin-Eosin (H&E) and Masson's trichrome for fibrosis. Presence of fibrosis, ductal proliferation, focal

duct cholestasis, portal tract expansions, portal inflammation, polymorphonuclear leukocytes (PNL), and hepatocyte necrosis in the sections were examined. Histopathological evaluation was performed with a micrometer inserted objective (x200 magnification, Nikon Eclipse 80i) or light microscopy (x100 magnification, Nikon Eclipse 80i) in 10 different areas.

### **Statistical analysis**

Data obtained in this study were compared using SPSS (Statistical Package for Social Sciences) 10.0 statistical program. Values are shown as mean  $\pm$  SD (Standard Deviation). One-Way ANOVA with post hoc Tukey b test was used for the evaluation of weight, biochemical results and histopathological results between groups, and Kruskal–Wallis test was used for the comparison of the parameters that did not show normal distribution and Mann–Whitney U test was used to determine the statistically different groups. The difference was considered significant when the p value was less than 0.05.

### **Results**

After 21 days of follow-up, Groups 2, 3, 4, and 5, all of which had undergone EHBT obstruction, were found to have significantly increased weight loss compared to the control group ( $p < 0.05$ ). In Group 2, rats lost more weight than the rats in Groups 3, 4, and 5 ( $p < 0.05$ ). In Group 5, rats lost less weight than the rats Groups 3 and 4 ( $p < 0.05$ ) (Table 1).

The evaluated biochemical comparisons of the groups are presented in Table 2. According to this, ALP, GGT, TB, AST, ALT and TP values were found to be higher in all groups with ligation compared to the control group ( $p < 0.05$ ). ALP, GGT, AST and ALT values of Groups 3, 4, and 5 were significantly lower than the values of Group 2 ( $p < 0.05$ ). TP

values were significantly higher in Group 3 compared to Groups 2, 4, and 5 ( $p < 0.05$ ). GGT and AST values of Group 4 were found to be lower compared to Groups 3 and 5 ( $p < 0.05$ ). The TP values of Group 5 were found to be significantly lower compared to Group 4 ( $p < 0.05$ ).

**Table 1.** Average weights of the rats before and after the EHBT obstruction.

Groups	Weight (gr)	
	EHBT obstruction before	EHBT obstruction after
Group 1	126.4±7.6	167.0±10.0
Group 2	138.9±6.1	114.3±7.3
Group 3	170.3±6.7	153.6±8.3
Group 4	172.5±6.1	153.3±6.4
Group 5	177.3±5.8	166.5±5.7

EHBT: Extrahepatic biliary tract

Histopathological examination revealed no histopathological and morphological abnormalities in H&E and Masson's trichrome staining in the control group (Figure 1A, B). The histopathological examination of liver tissues from Group 2 rats showed fibrosis, ductal proliferation, focal ductal cholestasis, portal tract expansion, portal inflammation, PNL, and hepatocyte necrosis. Connective tissue increase was detected in the portal and periportal area in Masson's trichrome staining (Figure 2A, B). In the histopathological examination of the liver tissues of Group 3 rats, we detected less proliferation and inflammatory cell infiltration sites in the portal and periportal biliary ducts. Masson's trichrome staining showed less deposition of connective tissue in the portal and periportal area (Figure 3A, B). In histopathological examination of liver tissues of Group 4 rats, decreased proliferation and inflammatory cell infiltration areas were detected in the portal and periportal biliary ducts.

**Table 2.** Biochemical comparisons of the groups.

Groups	ALP (units/l)	GGT (units/l)	TB (mg/dl)	AST (units/l)	ALT (units/l)	Total Protein (units/l)
Group 1	198.4±21.7	7.3±1.2	0.07±0.02	177.7±36.7	63.2±7.4	4.7±0.8
Group 2	387.0±8.4*	49.0±3.5*	10.6±2.3*	562.0±21.0*	142.0±4.7*	6.0±0.2*
Group 3	299.3±37.5*‡	27.7±3.6*‡	11.6±2.3*	371.3±69.4*‡	92.6±3.5*‡	5.3±0.7*†
Group 4	259.8±58.0*‡	13.5±2.6*‡Δ	12.2±0.6*	234.7±59.5*‡Δ	70.0±6.2*‡	6.0±0.2*
Group 5	303.8±44.8*‡	24.0±5.9*‡	9.9±0.9*§	345.2±62.8*‡	74.2±13.2*‡	6.1±0.2*

\*Group 1 vs Groups 2, 3, 4, 5,  $p < 0.05$

† Group 3 vs Groups 2, 4, 5,  $p < 0.05$

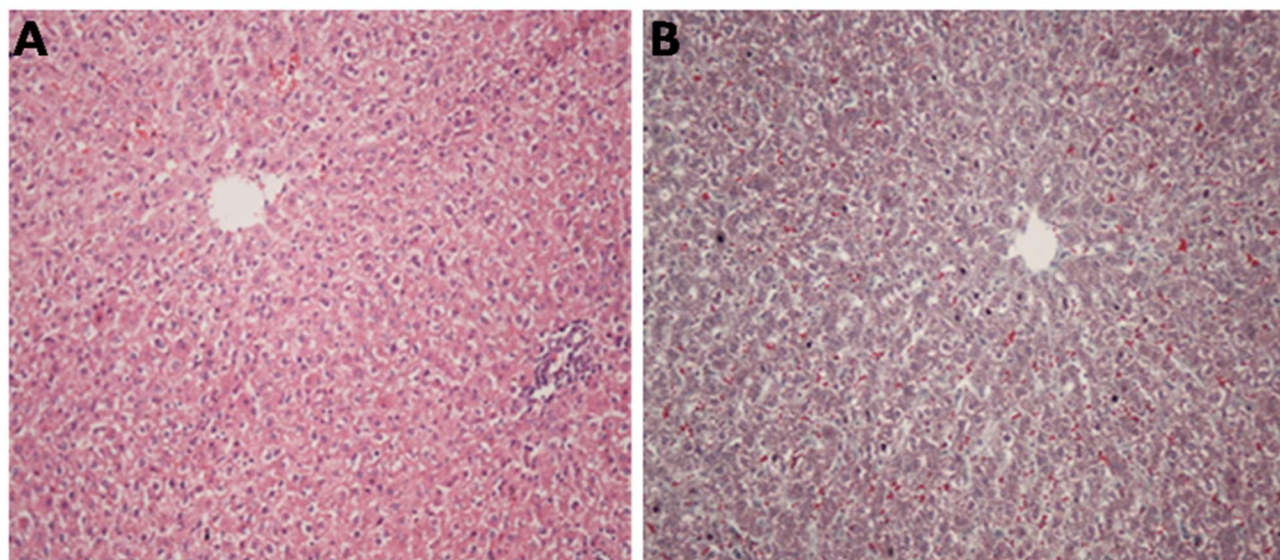
§ Group 5 vs Group 4,  $p < 0.05$

‡ Group 2 vs Groups 3, 4, 5,  $p < 0.05$

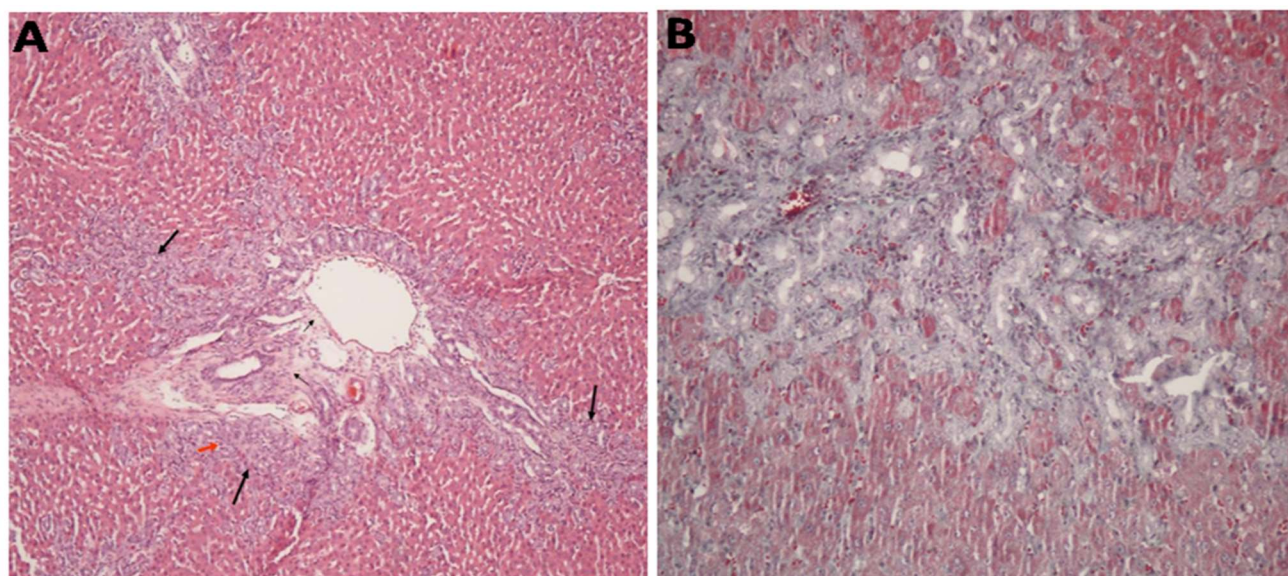
Δ Group 4 vs Groups 3 and 5,  $p < 0.05$

Masson's trichrome staining showed less accumulation of the connective tissue in the portal and periportal area (Figure 4A, B). When the histopathological findings of Group 5 rats were compared to those of Group 2,

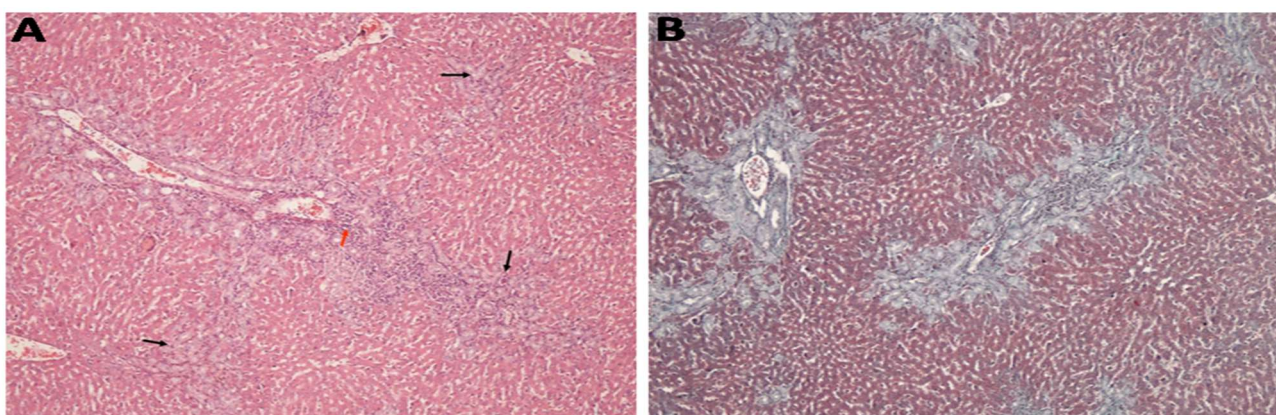
there was a significantly decreased proliferation in portal and periportal biliary ducts and a lesser degree of reduction in inflammatory cell infiltration and a slight decrease of fibrosis areas (Figure 5A, B).



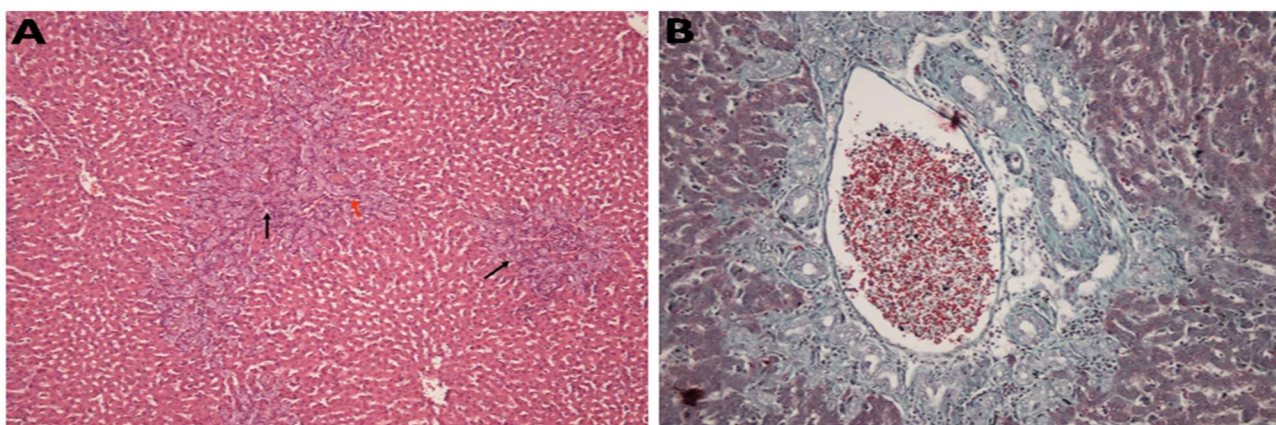
**Figure 1.** Normal histological appearance detected in liver tissue by H&E and Masson's trichrome staining in Sham-Control group (Group 1). **A** Normal histological appearance of the liver in Sham-Control (Group 1) (H&E, X200). **B** Normal histological appearance of the liver by Masson's trichrome staining in Sham-Control (Group 1) (Masson's trichrome, X200).



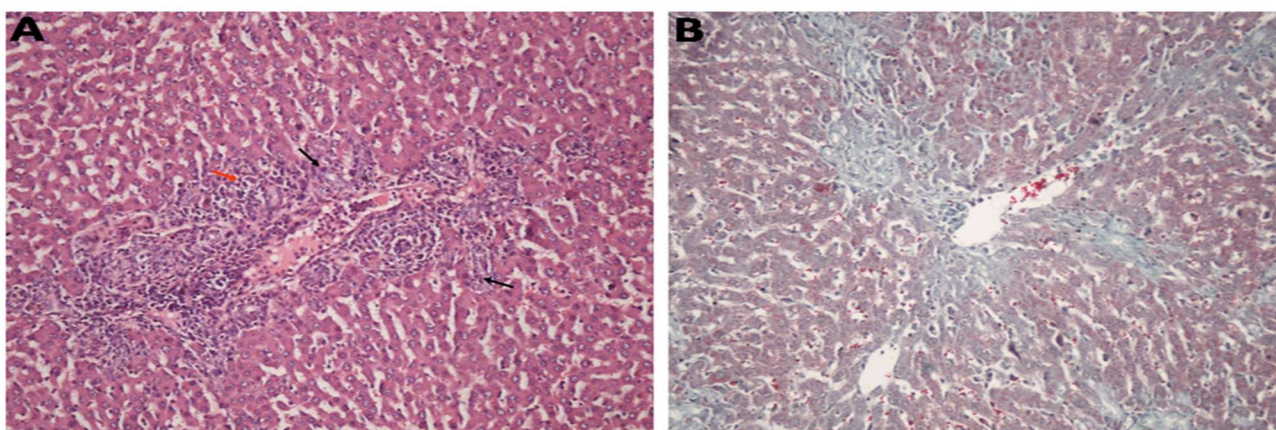
**Figure 2.** Histological damage detected in liver tissue by H&E and Masson's trichrome staining of group 2 rats that underwent EHBTO obstruction and were not given any drug. **A** Edema (thin black arrows), inflammatory cell infiltration (red arrow) findings around the portal area where ductal proliferation (thick black arrows) is observed (H&E, X100). **B** Appearance of marked connective tissue increase (Masson's trichrome, X200).



**Figure 3.** Histological damage detected in liver tissue by H&E and Masson's trichrome staining of Group 3 rats that underwent EHBT obstruction and received 2.5g / kg UDCA. **A** Proliferations in the portal and periportal biliary ducts (black arrows), areas of inflammatory cell infiltration (red arrow) with a minimal decrease compared to the findings observed in Group 2. (H&E, X100). **B** Minimal reduction in myofibroblastic proliferation compared to Group 2 (Masson's trichrome, X100).



**Figure 4.** Histological damage detected in liver tissue by H&E and Masson's trichrome staining in Group 4 rats that underwent EHBT obstruction and received 30 mg / kg COX-2 inhibitor. **A** Slightly decreased portal and periportal biliary ducts proliferation (thick black arrow), inflammatory cell infiltration areas (red arrow) compared to Group 2 (H&E, X100). **B** Less connective tissue accumulation in the portal and periportal area in Masson's trichrome staining compared with Group 2 (Masson's trichrome, X100).



**Figure 5.** Histological damage detected in liver tissue by H&E and Masson's trichrome staining of Group 5 rats that underwent EHBT ligation and received 2.5 g / kg of UDCA and 30mg / kg of COX-2 inhibitor. **A** Significant reduction in proliferation in portal and periportal biliary ducts (thick black arrows) and a smaller decrease in inflammatory cell infiltration (red arrow) compared to Group 2 (H&E, X100). **B** Fibrosis areas showing a slight decrease compared to Group 2 (Masson's trichrome, X100).

The evaluated histopathological comparisons of the groups are presented in Table 3. There was a statistically significant difference between Groups 2, 3, 4, and 5 and Group 1 in terms of fibrosis, ductal proliferation, focal ductal cholestasis, portal tract expansion and portal inflammation ( $p < 0.05$ ). The amount of hepatocyte necrosis was significantly higher in Groups 2 and 3 compared to Group 1 ( $p < 0.05$ ). No significant difference was found between Groups 4 and 5 and Group 1 ( $p > 0.05$ ). A statistically significant difference was found in the comparison of Groups 4 and 5 with Group 2 in terms of focal ductal cholestasis ( $p < 0.05$ ).

$< 0.05$ ). There was a statistically significant difference between Group 5 and Group 3 in terms of PNL ( $p < 0.05$ ). In terms of hepatocyte necrosis, a statistically significant difference was found in the comparison of Groups 3, 4, and 5 with Group 2 ( $p < 0.05$ ).

### Discussion

Enterohepatic circulation of bile acids allows the absorption of fats and fat-soluble vitamins from the gut and eliminates metabolic by-products such as cholesterol, toxins and bilirubin from the liver. Normal bile formation is due to the transcriptional coordination regulated by both posttranscriptional

**Table 3.** Evaluated histopathological measurements of the groups after 21 days of follow-up.

Groups	Fibrosis	Ductular Proliferation	Focal Ductular Cholestasis	Portal Tract Expansion	Portal Inflammation	PNL	Hepatocyte Necrosis
Group 1	0±0	0±0	0±0	0±0	0.2±0.4	0.1±0.3	0±0
Group 2	2.6±0.5*	2.9±0.3*	1.9±0.7*	2.7±0.4*	2.7±0.4*	1.9±0.5*	2.3±0.4*#
Group 3	2.2±0.6*	2.3±0.4*	1.4±0.5*	2.3±0.4*	1.1±0.3*§	1.0±0.0*§	0.8±0.4*#◆
Group 4	2.2±0.7*	2.5±0.8*	1.1±0.3*Δ	2.5±0.5*	1.2±0.4*§	0.7±0.4*§	0.4±0.5◆
Group 5	2.1±0.8*	2.1±0.8*†	1.0±0.0*Δ	2.4±0.6*	1.6±0.5*§	0.3±0.4*§¶	0.4±0.5◆

Values: Mean ± SD; PNL: Polymorphonuclear leukocyte.

\* Group 1 & Groups 2, 3, 4 and 5,  $p < 0.05$ ; # Group 1 & Groups 2 and 3,  $p < 0.05$ ; Δ Group 2 & Groups 4 and 5,  $p < 0.05$ ; † Group 2 & Group 5,  $p < 0.05$ ; § Group 2 & Groups 3, 4 and 5,  $p < 0.05$ ; ¶ Group 3 & Group 5,  $p < 0.05$ ; ◆ Group 2 & Groups 3, 4 and 5,  $p < 0.05$

Similarly, there was a statistically significant difference between Group 5 and Group 2 in terms of ductular proliferation ( $p < 0.05$ ). In terms of portal inflammation and PNL, a statistically significant difference was found between Groups 3, 4, and 5 and Group 2 ( $p$

mechanisms and nuclear receptors, together with the appropriate function of membrane transport systems in the enterohepatic pathway such as hepatocytes, bile duct epithelial cells (cholangiocytes), and enterocytes [8]. Cholestasis, known as a breakdown of the

biliary stream or flow, causes hepatotoxicity due to the accumulation of bile acids and other toxins in the liver and damage to the intracellular compartments and cell membranes. The most common causes of cholestasis in the neonatal period are biliary atresia and choledochal cyst. In addition, cholestasis is a component of many liver diseases such as cholelithiasis, cholestasis of pregnancy, primary biliary cirrhosis, and primary sclerosing cholangitis [9]. Cholestatic liver injury is also a major cause of chronic liver disease. Chronic retention of toxic bile acids is an important mechanism for cell toxicity, including oxidative stress, apoptosis, and fibrosis [10]. In histological analysis of liver sections rats that underwent BDL, bile duct proliferation, parenchymal necrosis, and inflammatory cell infiltration were found to be increased [11].

In rats that underwent EHBT ligation according to the method described by Criado et al. [7], there was an increase in biochemical values (ALP, GGT, TB, AST, ALT and TP) compared to the control group, and fibrosis, ductal proliferation, focal ductal cholestasis, portal tract expansion, portal inflammation, PNL increase, and hepatocyte necrosis were observed histopathologically in the liver. This model, which we applied, caused a stasis in the intrahepatic biliary tract and was evaluated as a suitable model. Similarly, biochemical values were found to be higher and histopathological changes were observed in Groups 3, 4 and 5, which had EHBT ligation and were treated with different drugs, compared to the control group. However, biochemical and histopathological results were found to be better in Groups 3, 4, and 5, which were treated with UDCA, the COX-2 inhibitor celecoxib and the combination of celecoxib

and UDCA, respectively, than in group 2, which had only EHBT ligation.

UDCA is an endogenous tertiary natural bile acid that normally constitutes 0.1-5% of the bile pool found in the human. UDCA is the only drug approved by the FDA for chronic cholestatic liver disease in the treatment of primary biliary cirrhosis, and its efficacy in the dissolution of cholesterol gallstones has been demonstrated [12]. It inhibits cholesterol absorption in intestines, and cholesterol secretion and cholesterol crystal formation in bile. UDCA protects the lipid layer of the liver cell membrane against the toxic effect of hydrophobic bile salts (cytoprotective effect) [13]. It prevents the inclusion of bile acids such as kenodeoxycholic acid and cholic acid in the enterohepatic circulation and constitutes 40% to 55% of total bile salts, resulting in the formation of copious amounts bile rich in bicarbonate (cholehepatic shunt) [14]. Oral administration of various bile salts to obstructive jaundice rats eliminates endotoxemia by reducing intestinal absorption of endotoxin. UDCA has a hepatoprotective effect by protecting hepatocytes against oxidative damage in obstructive jaundice rats. It was also claimed that bile salts have lytic effects on the cell walls of intraluminal bacteria [15]. UDCA reduces excess HLA-Class I antigen expression in hepatocytes, and HLA-Class II antigen expression in biliary epithelium [16]. Abdelmalek et al. gave UDCA to a patient with steatohepatitis for one year. The patient's liver function tests improved, were elevated again after discontinuation, and subsequently decreased again when the drug was reinitiated [17]. Laurin et al. gave 13-15 mg/kg/day UDCA to 24 non-alcoholic liver patients for one year and found a significant reduction in steatosis, ALT, AP, and GGT levels at the end of treatment.



They thought that there was an association between the improvement and the membrane stabilizing and cytoprotective effects of UDCA [18]. In a study by Barone et al. with partial bile duct ligation in rats, UDCA increased cholangiocyte proliferation; they suggested that this supports the use of UDCA in the treatment of cholestatic chronic liver diseases. They reported that UDCA reduced liver damage and apoptosis and delayed ductopenic stage by stimulation of proliferation [19]. Experimental cholestasis models and hepatocytes in which animals are treated with toxic bile acids have been reported to have decreased liver glutathione (GSH) levels. Decrease in GSH levels endangers antioxidant defense and contributes to injury. In other studies, a decrease in glutamylcysteine ligase (GCL) activity has been shown [10]. It was reported that UDCA inhibited the decrease of GCL levels during chronic cholestasis and increased GCL levels [20]. In an experimental study conducted by Yang et al. [10], it was suggested that UDCA maintains GSH levels and prevents liver damage. In the study by Kitani et al., it was shown that there was a significant reduction of microvascular fat formation in hepatocytes and a decrease in AST, ALT, and GGT levels after UDCA was given to the group of animals with obstructive jaundice [21]. Beuers et al. [22] suggested that the beneficial effect of UDCA in cholestasis-induced rats may be due to calcium-dependent stimulation of vesicular exocytosis by UDCA. Al-Hathlol et al. [23] found cholestasis in 13 babies with very low birth weight, most with necrotizing enterocolitis when the babies were about 36 days old, and observed a significant decrease in bilirubin levels with treatment of UDCA for 3 months.

The enzyme cyclooxygenase (COX) has been shown to increase as a result of active

inflammation in the case of chronic cholestasis. The enzyme cyclooxygenase has two isoforms: COX-1 and COX-2. COX-1 is structurally deposited, i.e. it is always present because of its continuous synthesis in the cells in which it is produced. COX-2 increases as a result of inflammation, mitogenic stimuli, and various growth factors. Induction of the COX-2 enzyme results in prostaglandin synthesis in inflamed tissues. In the development of early fibrosis in rats, vasoconstrictive endothelin 1 (ET-1) and thromboxane A2 (TXA2) in Kupffer cells play an important role in the development of hepatocellular injury and portal hypertension. COX-2 is one of the key enzymes involved in the increase of ET-1 and TXA2 during prostaglandin synthesis [24]. This is related to the fact that COX-2 is a regulatory enzyme that is involved in the synthesis of prostaglandins and their metabolites in inflammation, cellular proliferation, anti-apoptosis, cell growth, and angiogenesis. Therefore, inhibition of COX-2 has been a pharmacological target to reduce prostaglandin production in cases of chronic inflammation and fibrosis. The antifibrotic effect of COX-2 inhibitors has been previously reported in several *in vivo* and *in vitro* experimental studies such as renal interstitial fibrosis and desmoplasia. In addition, selective COX-2 inhibitors are known to play a role in the liver as an antifibrotic agent [25-27]. It has been suggested that cholestasis causes COX-2 accumulation in the liver of rats that underwent BDL and that the selective COX-2 inhibitor meloxicam reduces liver fibrosis caused by BDL. This effect of meloxicam was associated with a reduction of cyclooxygenase activity in the liver and a decrease in liver TGF- $\beta$ 1 [28]. Yu et al. [29] demonstrated the role of celecoxib in cholestatic liver fibrosis using morphological and molecular biology data in

their study of celecoxib in rats with biliary tract ligation. They reported that celecoxib was protective against liver inflammation in the early stages in rats that underwent BDL, but not on liver fibrosis.

In our study, it was found that ALP, GGT, AST and ALT values of Groups 3, 4 and 5, which we gave drug treatment, decreased significantly compared with Group 2, and liver function was better. The TP values of Group 3, which received UDCA therapy, were found to be lower compared to TP values of Groups 2, 4, and 5, and the difference was statistically significant. It was determined that GGT and AST values of Group 4, which was treated with celecoxib, were lower in comparison with GGT and AST values of Groups 3 and 5, and the difference was statistically significant. The TB values of Group 5 rats treated with the combination of UDCA and celecoxib were found to be significantly lower in comparison with Group 4. The histopathological examination of all groups with EHBT ligation revealed significant changes in ductular proliferation, focal ductal cholestasis, portal tract expansion, portal inflammation, and increase in polymorphonuclear leukocytosis, hepatocyte necrosis, and fibrosis compared with control group (Group 1). However, it was found that hepatocyte necrosis of Groups 4 and 5 was present compared to Group 1, although the increases were not significant. In terms of hepatocyte necrosis, Groups 2 and 3 were higher compared to Group 1. Although the results of both the biochemical tests and the histopathological examination of all groups that received a drug treatment were better compared to Group 2, the results of both the biochemical and histopathological evaluations were found to be more positive in the group receiving celecoxib. More favorable results in histopathological examination of liver tissues

were observed in Group 5 rats, where the additive effects of both drugs were obtained with the combination of a COX-2 inhibitor and UDCA. These positive effects on the liver suggest that these may be the result of a combination of the cytoprotective and antioxidant effects of UDCA and the anti-inflammatory, cell proliferation-inhibiting, and anti-apoptotic effects of the COX-2 inhibitor celecoxib.

### **Conclusion**

Our findings suggest that the addition of celecoxib to UDCA may be an effective complementary treatment for cholestatic diseases by reducing inflammation and fibrosis in the liver. The combination of celecoxib and UDCA reduced liver damage in rats that underwent biliary tract ligation. Clinically, COX-2 and UDCA can be used separately or together to prevent liver fibrosis in the preoperative period. However, further studies on this issue are necessary.

**Conflict of Interest:** *No conflict of interest was declared by the authors.*

**Funding sources:** *None*

### **References**

- [1] Bishop WP. Neonatal cholestasis. In: Donnellan WL, editor. *Abdominal Surgery of Infancy and Childhood*. 31. Luxembourg: Harwood Academic Publishers; 2004. p. 1-17.
- [2] Kimura YI. Biliary atresia. In: Donnellan WL, editor. *Infancy and Childhood*. 32. Luxembourg: Harwood Academic Publishers; 2004. p. 1-13.
- [3] Ohi NM. The jaundiced infant: Biliary atresia and other obstructions. In: O'Neill JA, editor. *Pediatric Surgery*. St. Louis: Mosby; 1998. p. 1465-81.

- [4] Josef E. Fischer FQ, Herni R. Ford, Ergun O. *Mastery of Surgery*, 5ed. Philadelphia: Lippincott Williams & Wilkins 2007.
- [5] Luketic VA, Sanyal AJ. The current status of ursodeoxycholate in the treatment of chronic cholestatic liver disease. *Gastroenterologist*. 1994;2(1):74-79.
- [6] Okazaki T, Kobayashi H, Yamataka A, Lane GJ, Miyano T. Long-term postsurgical outcome of biliary atresia. *J Pediatr Surg*. 1999;34(2):312-15.
- [7] Criado M, Flores O, Ortiz MC, Hidalgo F, Rodriguez-Lopez AM, Eleno N, et al. Elevated glomerular and blood mononuclear lymphocyte nitric oxide production in rats with chronic bile duct ligation: role of inducible nitric oxide synthase activation. *Hepatology*. 1997;26(2):268-76.
- [8] Kullak-Ublick GA, Stieger B, Meier PJ. Enterohepatic bile salt transporters in normal physiology and liver disease. *Gastroenterology*. 2004;126(1):322-42.
- [9] Liu Y, Binz J, Numerick MJ, Dennis S, Luo G, Desai B, et al. Hepatoprotection by the farnesoid X receptor agonist GW4064 in rat models of intra- and extrahepatic cholestasis. *J Clin Invest*. 2003;112(11):1678-87.
- [10] Yang H, Ramani K, Xia M, Ko KS, Li TW, Oh P, et al. Dysregulation of glutathione synthesis during cholestasis in mice: molecular mechanisms and therapeutic implications. *Hepatology*. 2009;49(6):1982-91.
- [11] He H, Mennone A, Boyer JL, Cai SY. Combination of retinoic acid and ursodeoxycholic acid attenuates liver injury in bile duct-ligated rats and human hepatic cells. *Hepatology*. 2011;53(2):548-57.
- [12] Kumar D, Tandon RK. Use of ursodeoxycholic acid in liver diseases. *J Gastroenterol Hepatol*. 2001;16(1):3-14.
- [13] Heuman DM, Pandak WM, Hylemon PB, Vlahcevic ZR. Conjugates of ursodeoxycholate protect against cytotoxicity of more hydrophobic bile salts: in vitro studies in rat hepatocytes and human erythrocytes. *Hepatology*. 1991;14(5):920-26.
- [14] Erlinger S. Hypercholeretic bile acids: a clue to the mechanism? *Hepatology*. 1990;11(5):888-90.
- [15] Aldemir M, Geyik MF, Kokoglu OF, Buyukbayram H, Hosoglu S, Yagmur Y. Effects of ursodeoxycholic acid, glutamine and polyclonal immunoglobulins on bacterial translocation in common bile duct ligated rats. *ANZ J Surg*. 2003;73(9):722-26.
- [16] Calmus Y, Gane P, Rouger P, Poupon R. Hepatic expression of class I and class II major histocompatibility complex molecules in primary biliary cirrhosis: effect of ursodeoxycholic acid. *Hepatology*. 1990;11(1):12-15.
- [17] Abdelmalek M, Ludwig J, Lindor KD. Two cases from the spectrum of nonalcoholic steatohepatitis. *J Clin Gastroenterol*. 1995;20(2):127-30.
- [18] Laurin J, Lindor KD, Crippin JS, Gossard A, Gores GJ, Ludwig J, et al. Ursodeoxycholic acid or clofibrate in the treatment of non-alcohol-induced steatohepatitis: a pilot study. *Hepatology*. 1996;23(6):1464-67.
- [19] Barone M, Maiorano E, Ladisa R, Pece A, Berloco P, Strazzabosco M, et al. Ursodeoxycholate further increases bile-duct cell proliferative response induced by partial bile-duct ligation in rats. *Virchows Arch*. 2004;444(6):554-60.

- [20] Serviddio G, Pereda J, Pallardo FV, Carretero J, Borrás C, Cutrin J, et al. Ursodeoxycholic acid protects against secondary biliary cirrhosis in rats by preventing mitochondrial oxidative stress. *Hepatology*. 2004;39(3):711-20.
- [21] Kitani K. Hepatoprotective effect of ursodeoxycholic acid in experimental animals. In: Paumgartner G, editor. *Strategies for the Treatment of Hepatobiliary Diseases*. Boston: Kluwer Academic Publishers; 1990. p. 43-56.
- [22] Beuers U, Nathanson MH, Isales CM, Boyer JL. Tauroursodeoxycholic acid stimulates hepatocellular exocytosis and mobilizes extracellular Ca<sup>++</sup> mechanisms defective in cholestasis. *J Clin Invest*. 1993;92(6):2984-93.
- [23] Al-Hathlol K, Al-Madani A, Al-Saif S, Abulaimoun B, Al-Tawil K, El-Demerdash A. Ursodeoxycholic acid therapy for intractable total parenteral nutrition-associated cholestasis in surgical very low birth weight infants. *Singapore Med J*. 2006;47(2):147-51.
- [24] Meng JP, Ceryak S, Aratsu Z, Jones L, Epstein L, Bouscarel B. Biphasic regulation by bile acids of dermal fibroblast proliferation through regulation of cAMP production and COX-2 expression level. *Am J Physiol Cell Physiol*. 2006;291(3):C546-54.
- [25] Nam KT, Hahm KB, Oh SY, Yeo M, Han SU, Ahn B, et al. The selective cyclooxygenase-2 inhibitor nimesulide prevents *Helicobacter pylori*-associated gastric cancer development in a mouse model. *Clin Cancer Res*. 2004;10(23):8105-13.
- [26] Yao M, Lam EC, Kelly CR, Zhou W, Wolfe MM. Cyclooxygenase-2 selective inhibition with NS-398 suppresses proliferation and invasiveness and delays liver metastasis in colorectal cancer. *Br J Cancer*. 2004;90(3):712-19.
- [27] Zuo Y, Ma J, Gu Y, Yang H, Lin S. The renal protective effect of selective cyclooxygenase-2 inhibitor on obstructive nephropathy. *Zhonghua Nei Ke Za Zhi*. 2002;41(12):825-28.
- [28] Kim SM, Park KC, Kim HG, Han SJ. Effect of selective cyclooxygenase-2 inhibitor meloxicam on liver fibrosis in rats with ligated common bile ducts. *Hepatology Res*. 2008;38(8):800-9.
- [29] Yu J, Hui AY, Chu ES, Go MY, Cheung KF, Wu CW, et al. The anti-inflammatory effect of celecoxib does not prevent liver fibrosis in bile duct-ligated rats. *Liver Int*. 2009;29(1):25-36.